The Project on Sustainable Livestock Development for Rural Sindh "PSLD"
(JICA Technical Cooperation)

Textbook for Diagnosis and Treatment of Reproductive Disorder of Dairy Cattle and Buffalo

November 2018

This textbook has been developed for the use of livestock professionals. The Livestock and Fisheries Department, Government of Sindh welcomes your comments and suggestion to improve this material.

Developed by The Project on Sustainable Livestock Development for Rural Sindh
First printing
(Second) printed November 2018
Sponsored and Produced by The Project on Sustainable Livestock Development for Rural Sindh (PSLD) and Japan International Cooperation Agency (JICA)

Preface

Livestock is the largest sub-sector in agriculture of Pakistan, contributing 11.4 percent to overall GDP of the country. Livestock plays vital role in rural economy and livelihood of rural poor, so as in rural Sindh. It is a source of cash income, nutrition and sometimes only asset for the rural and marginalized people.

The Project on Sustainable Livestock Development for Rural Sindh (The Project) is the 5 years technical cooperation project implemented in collaboration with the Livestock and Fisheries Department, Government of Sindh and Japan International Cooperation Agency (JICA), Government of Japan, aiming for creating foundations of sustainable livestock sector development in Sindh province, which benefit small scale dairy farmers who comprises more than 80 percent of the sector. The Project was initiated in February 2014 and implemented in 5 pilot districts, namely Matiari, Hyderabad, Tando Muhammad Khan, Tando Allahyar and Badin. The Project focused on development of appropriate technologies for dairy farming. Throughout five years of implementation, appropriate technologies were developed, piloted and verified for the use of small scale formers in Sindh province. Along with the appropriate technologies, useful basic technologies for livestock professional technicians were developed. The technologies range over 7 areas, namely, farm management, marketing, feeding management, fodder, animal health, animal reproduction and genetic improvement. The Project worked on effective utilization of livestock resources, i.e. calves and dry buffaloes in the commercial cattle colony as well. Method for salvation of calves and dry buffaloes were verified.

Technologies developed by the Project are compiled as textbooks, guidelines and booklets for wider application and dissemination to professional technicians, and ultimately to farmers. The Livestock and Fishery Department hope that these series of publications will widely be used by livestock professional technicians both public and private and dairy farmers in Sindh province for uplifting their livelihood.

Director General / Project Coordinator
The Livestock and Fisheries Department
Government of Sindh

Foreword

The Project on Sustainable Livestock Development for Rural Sindh is implemented in Southern parts of Sindh Province, Pakistan in collaboration with Livestock and Fisheries Department, Government of Sindh and Japan International Cooperation Agency (JICA). The Project was supported by the team of Japanese experts led by Mr. Hiroshi Okabe.

The baseline survey on small and medium scale dairy farmers conducted in the beginning of the Project revealed that majority of dairy farmers availed veterinary services only at the time of serious illness or dystocia of their animals. Dairy farmers apply traditional methods when their animals suffer from slight illness and do not use services of reproductive diagnosis and treatment for reproductive disorder of their animals. Reproductive disorder is not fatal disease and does not demand emergency treatment. Dairy farmers just wait without any diagnosis and treatment of unpregnant animals until they decide to cull at some point of time. This is normal practice which has been exercised in rural Sindh. Expertise on animal reproduction in the area was underdeveloped. The Project had to start technical guidance on animal reproduction from scratch.

To produce tangible results on improvement of conception rate of animals, both technical guidance to dairy farmers and to veterinary doctors are required in parallel. For dairy farmers, technical guidance on improvement of nutritious condition of animals, heat detection and reduction of stress are needed. For the veterinary doctors, they need to be trained as skilled technicians who can diagnose and treat reproductive disorder. Diagnosis and treatment of reproductive disorder through rectal palpation requires profound techniques which can be developed through untiring efforts over considerable time period. Training on animal reproduction organized by the Project is time-bound. Trainees are expected to obtain most essential basic knowledge and techniques in a training and continue making efforts to accumulate their experiences at farms to improve their skills by themselves after a training. The Project hopes that this text book will be of use for trainees to improve their skills in the field.

Japanese technical cooperation in the field of animal reproduction towards developing countries is increasing year by year. For smooth and proper technology transfer from Japanese experts to technicians in developing countries, 'Manual for diagnosis and treatment of reproductive disorder in dairy cattle' was developed by Japan Livestock Technology Association upon request of Japanese Ministry of Agriculture, Forestry and Fisheries. With the permission of Japan Livestock Technology Association, this textbook was composed of the extract from the above manual with some modification by Japanese experts and Pakistani technicians for the use of technicians in Pakistan. We express our gratitude to Japanese Ministry of Agriculture, Forestry and Fisheries as well as Japan Livestock Technology Association for their kind cooperation.

November 2018

Editor in charge

Dr. Hideo TOMINAGA / Expert on Livestock Technology Development

Contributors for compiling this textbook

Pakistani technicians

- Dr. Akthar Ali Shahani, Main counterpart specialized in Animal Reproduction
- Dr. Naeem Siddique Ansari, Sub-counterpart specialized in Animal Reproduction

Japanese experts

- Dr. Kazuhiro ONO, Expert on Animal Reproduction
  (Ex-officer of Chiba Prefectural Federation of Agricultural Mutual Aid Association "Chiba-Kyosai)
- Dr. Takeshi ABE, Expert on Animal Reproduction
  (Ex-officer of Chiba Prefectural Federation of Agricultural Mutual Aid Association "Chiba-Kyosai)

Contents

Abbreviation List

ACTH	Adrenocorticotropic Hormone
APG	Anterior Pituitary Gonadotropin
AU	Armour Unit
CCL	Cystic Corpus Luteum
CIDR	Controlled Internal Drug Release
CRH	Corticotropin Releasing Hormone
E	Estrogen
E_1	Estrone
E_2	Estradiol
E_3	Estriol
E_1S	Estrone Sulfate
eCG	equine Chorionic Gonadotropin
EGF	Epidermal Growth Factor
EIA	Enzyme Immunoassay
ES Cell	Embroyonic Stem Cell
FC	Follicular Cyst
GnRH	Gonadotropin Releasing Hormone
GTH	Gondotropic Hormone
hCG	human Chorionic Gonadoptropin
IGF	Insulin-like Growth Factor
IL-1	Interleukin-1
IU	International Unit
LC	Luteal Cyst
LH	Luteinizing Hormone
ng	Nanogram (10^{-9}g)
NGF	Neuro Growth Factor
OT	Oxytocin
P_4	Pregesterone
PCF_{2a}	Prostaglandin F_{2a}
PCR	Polymerase Chain Reaction
Pg	Picogram (10^{-10}g)
PIH	Prolactin Release Inhibiting Hormone
PL	Placental Lactogen
PMSG	Pregnant Mare Serum Gonadotropin (equine Chorionic Gonadtropin)
PRH	Prolactin Releasing Hormone
PRID	Prosgesterone Releasing Intravaginal Device (Another name:CIDR)
PRL	Prolactin
Rab U	Rabbit Unit
RI	Radioisotope
RIA	Radioimmunoassay
SRY	Sex-determing Region Y
T	Testosterone
TGF	Transforming Growth Factor
μg	Microgram(10^{-6}g)

(Note) Estrogen and Progesterone [1]

[1] Estrogen: Number of E are OH groups (hydroxyl groups) in the steroid chemical formula.

Progesterone: There is the fourth double bond of steroid in chemical formula of progesterone, it is abbreviated as P_4.

Chapter 1 Reproductive physiology of dairy cattle & buffalo

1.1 Structure of reproductive organs

Female reproductive organs are roughly divided into the ovary, oviduct, uterus, uterine cervix, vagina and vulva. Their locations in the body are as shown in Figures 1-1 and 1-2.

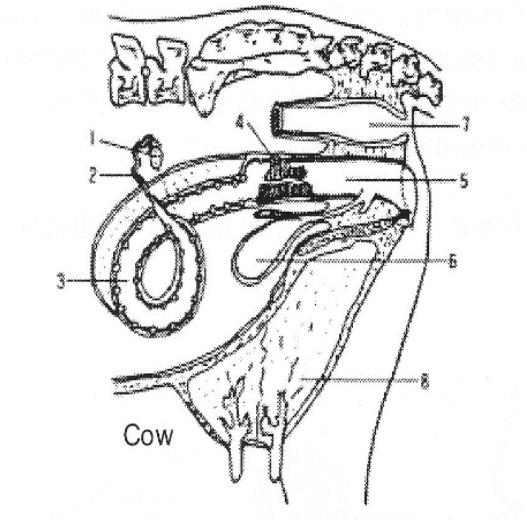

1. Ovary
2. Oviduct
3. Uterus
4. Uterine cerVix
5. Vagina
6. Bladder
7. Rectum

Figure 1-1 Reproductive organs of cows

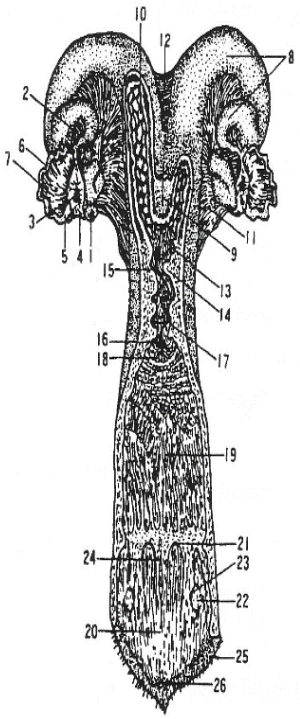

1. Ovary
2. Proper ligament of ovary
3. Abdominal opening of uterine tube
4. Ovarian fimbria
5. Ampulla of uterine tube
6. Isthmus of uterine tube
7. Mesosalpinx
8. Uterine horn
9. Velum uteri
10. Caruncle
11. Broad ligament of the uterus
12. Intercornial ligament
13. Uterine cavity and isthmus
14. Uterine cervix
15. Internal uterine orifice
16. External uterine orifice
17. Cervical canal

Figure 1-2 Reproductive organs of cows (partial section of the dorsal part)

1.1.1 Ovary

A cow has the left and right ovaries and follicular growth and maturation, ovulation, and luteal formation and regression occur in these ovaries of mature cows according to the estrous cycle.

1.1.2 Oviduct

The oviduct following the ovary serves as a route through which an emitted ovum is transported and is the location where the ovum encounter sperm and fertilization takes place. The oviduct consists of the infundibulum with fimbriae, ampulla and isthmus (see Figure 1-3). Fertilization occurs in the ampulla portion. A fertilized ovum descends within the oviduct and enters the uterus while undergoing cleavage. A fertilized ovum after the start of cleavage is generally referred to as an embryo.

A fertilized Ovum that started cleavage in the oviduct develops through the 2, 4, 8 cell stages into the morula stage. It further develops to form internal cavities (blastula cavities) in the gaps among cells where it stores protein-rich fluid. An embryo at this stage is referred to as a blastocyst.

An embryo enters the uterus when it is at the stage of morula or blastocyst, about 7 days after ovulation.

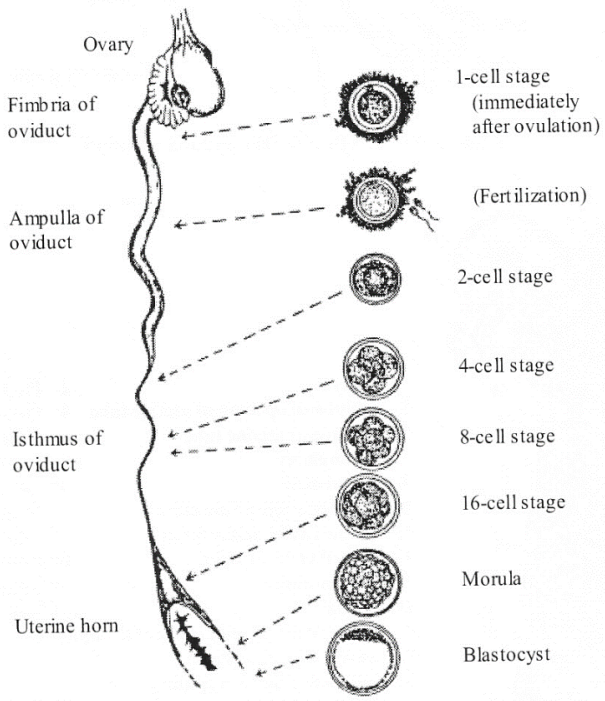

Figure 1-3 Descent of an Ovum in the oviduct (cow)

1.1.3 Uterus

An embryo that enters the uterus is implanted on the endometrium and continues to grow. It then gradually develops an external shape characteristic of adult cattle. The internal structures become similar to those of adult cattle to carry out functions. An embryo at this stage onward is referred to as a fetus. The pregnancy period is divided into the 1) ovum period, 2) embryonic period and 3) fetal period.

1.1.4 Uterine cervix

The lumen of the uterine cervix is referred to as the cervical canal. Circular folds are present on the internal surface of the cervical canal of cattle and the lumen is rigidly closed. The exit of the cervical canal on the uterine side is referred to as the internal uterine orifice and the one on the vaginal side the external uterine orifice.

1.1.5 Vulva

The pudendum refers to the end of the urogenital canal of female cattle and the exit to the outside of the body is referred to as the vulva.

1.2 Sexual maturity, estrous cycle, pregnancy, parturition, and return of estrus after parturition

1.2.1 Sexual maturity and breeding age

Sexually mature cows repeat estrus at certain intervals. In Holsteins, the ovary starts functioning at the age of 6-12 months (puberty) but female Holstein are usually capable of breeding after 18 months, and calving after the age of 28 months (Zebu cattle and buffalo reach puberty after 24 months and calving after 36 months). The first ovulation after puberty does not show any estrous signs in most cases and the first estrous cycle is short.

1.2.2 Estrous Cycle

(1) Emergence of estrous cycle

In non-pregnant sexually mature cows, a cycle consisting of follicular growth, ovulation, and luteal formation and regression is repeated in the ovary and estrus emerges when the ovarian follicle is mature. These periodical changes are referred to as the estrous cycle. The estrous cycle is generally divided into the estrous phase and the luteal phase, the latter of which is further divided into the luteal formation stage (early luteal phase), functional luteal stage (luteal peak phase) and the luteal regression stage (end luteal phase).

(2) Length of estrous cycle

In general, temperate zones including Japan, the length of the estrous cycle ranges from 18 to 25 days with that of heifer being 20 days and that of cow 21 days. This cycle is influenced by breed, season and age and extends to 22 days in old cows.

(3) Changes that occur in the reproductive organs during estrous cycle

1) Growth of ovarian follicles

A cow originally has several tens of thousands to a hundred thousand primordial ovarian follicles in its ovary. The process in which these primordial ovarian follicles mature is shown in Figures 1-4 (p.4) and 1-5 (p.4). They develop through the primary and secondary ovarian follicles into vesicular ovarian follicles (graafian follicles) and emit ova. However, not more than 200 primordial ovarian follicles mature and emit ova during a cow's lifetime and the remaining follicles degenerate in the ovary.

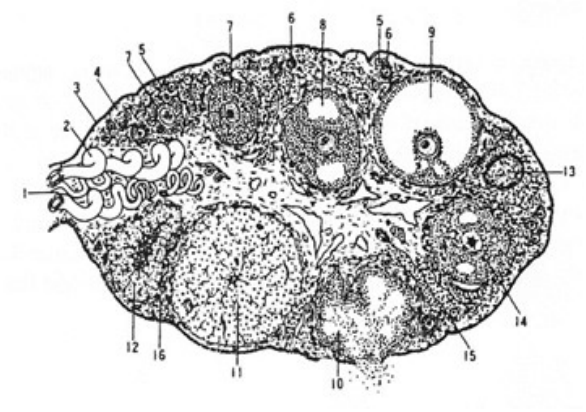

Figure 1-4 Schematic view of bovine ovary

1. Hilum of ovary
2. Blood vessel
3. Epithelium
4. Ovarian albuginea
5. Primordial ovarian follicle
6. Primary ovarian follicle
7. Secondary ovarian follicle
8. Growing mature ovarian follicle
9. Mature ovarian follicle
10. Ovarian follicle immediately after ovulation
11. Corpus luteum at functional luteal stage
12. Corpus luteum at luteolysis stage
13. Corpus albicans
14. Atretic follicle
15. Interstitial gland
16. Connective tissue

2) Maturity of ovarian follicles

A mature ovarian follicle is 12-24 mm in diameter and is enveloped with an external theca layer, internal theca layer and granulosa layer. An oocyte is enveloped with granulosa cells to form a germ hill and projects into the follicular antrum (see Figure 1-5 (p.4)). The follicular antrum is filled with follicular fluid.

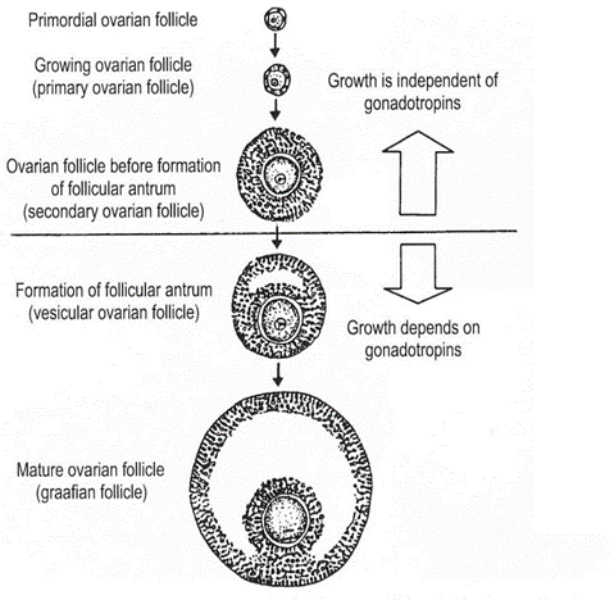

Figure 1-5 Development of ovarian follicle

Development from the primordial ovarian follicle to the stage before the formation of follicular antrum occurs in cows without hypophysis. The final development from the formation of follicular antrum to ovulation depends on gonadotropins. This second-stage development is shorter than the first-stage development. Maturity of an oocyte (resumption of meiosis and maturity of cytoplasm) only occurs after an LH surge.

3) Ovulation

Ovulation normally occurs after estrous and between 2 and 20 hours after estrous although it rarely occurs before the end of estrous. It most commonly occurs between 10 and 15 hours after estrus.

4) Formation and regression of the corpus luteum

Immediately after ovulation, the follicular antrum is filled with blood, some follicular fluid and leaked lymph fluid. Subsequently, luteal cells are formed by both surrounding granulosa and internal theca cells, the internal portion is enriched and the corpus luteum is formed. The corpus luteum is completed within 7-8 days of ovulation with a longitudinal length of 20mm functional corpus luteum. It continues developing and reaches a maximum longitudinal length of 20mm or more within 13-15 days of ovulation. After the functional corpus luteum stage, the corpus luteum starts rapid regression from the 17th to 18th day of the estrous cycle and shrinks and hardens. It also changes in color from orange during the functional corpus luteum stage to yellowish orange and finally to reddish brown (corpus luberum). The corpus luberum does not have the same function as the corpus luteum or excrete hormones. The pregnant corpus luteum remains on the ovarian surface for a long period after regression and is referred to as the corpus albicans.

(4) Estrous signs

Estrous signs in cows include a sharp look, increased sensitivity to sounds, reduced appetite, reduced rumination and loose stools. Estrous cows howl with a peculiar loud cry and wander about for bulls. They may mount on and be mounted by other cows raised together. They stand still and allow other cows to mount them when they are at estrous peaks. This behavior is referred to as a standing estrous and represents the estrous phase in a strict sense. The pudendum becomes congested and swollen and a large amount of mucus leaks from it.

(5) Optimum time of insemination

Identifying the start of estrous in cattle is important in determining the optimum time of insemination and achieving high conception rates. However, monitoring cattle continuously is difficult so various tools such as heat mount detectors, tail paint, chin balls and pedometers have been used and teasers (bulls for detecting estrus) that are treated in various ways have been experimentally introduced.

(6) Bleeding after ovulation

Some cows leak blood-like mucus or blood from the pudendum 1-4 days after the end of estrus. Leaks occur 2 days after the end of estrous in most cases and the incidence and amount of blood leaked is higher in nulliparae than in multiparae. Bleeding occurs at uterine mucous membranes. This bleeding indicates the end of estrus and helps predict the following estrus.

(7) Hormonal control of estrous cycle

Hormones that control the estrous cycle include those indicated in Table 1-1.

Table 1-1 Major hormones involved indicated in reproduction

Hormone-producing organs	Hormones	Chemical property	Molecular weight	Action
Hypothalamus	Gonadotropin releasing hormone (GnRH, LHRH)	Peptide	1,182	Promotes release of FSH and LH.
	Corticotropin releasing hormone (CRH)	Peptide	Approx. 4,900	Controls GnRH secretion (Controls gonad function under stress).
	Oxytocin (Stored in the posterior lobe of the pituitary gland. Also produced by the ovary)	Peptide	1,007	Promotes uterine contraction, calving, transportation of sperm and ova, and milk ejection. Most likely to have luteolytic action.
	Melatonin (Secreted by the pineal body)	Peptide	232	Involved in the seasonal expression of reproductive activity of seasonal breeders.
Anterior lobe of the pituitary gland	Follicle stimulating hormone (FSH)	Glycoprotein (heterodimer of and subunits)	41,000	Promotes follicular growth, spermatogenesis and estrogen secretion.
	Luteinizing hormone (LH)	Glycoprotein (heterodimer of and subunits)	29,000	Promotes ovulation and luteal function. Promotes secretion of progesterone, estrogen and androgen.
	Prolactin (PRL)	Simple protein	22,000	Promotes lactation and in some animal species, luteal function and progesterone secretion. Enhances maternal behavior. Promotes tissue and bone growth.
Placenta	Human chorionic gonadotropin (hCG)	Glycoprotein	14,500	Shows LH action. Maintains pregnant corpus luteum in primates.
	Pregnant mare serum gonadotropin (PMSG, eCG)	Glycoprotein	53,000	Shows mainly FSH action. Promotes formation of the accessory corpus luteum in horses.
	Placental lactogen (PL)	Glycoprotein	20,000 - 50,000	Controls nutritional supply from mother to fetus.
	Protein B			Unknown.
Gonad	Estrogen/follicle	Steroid (C-18)	270 - 290	Enhances female sexual activity. Promotes secondary sexual character, growth of reproductive tracts, uterine contraction and development of mammary ducts. Controls gonadotropin secretion. Promotes calcium absorption by bones. Shows assimilation action.
	Progesterone/corpus luteum	Steroid (C-21)	314	Promotes estrous behavior and helps reproductive tracts to prepare for implantation in conjunction with estrogen. Promotes secretion by the endometrium. Maintains pregnancy. Promotes growth of mammary glandular cells. Controls gonadotropin secretion.
	Testosterone/testis	Steroid (C-19)	Approx. 290	Promotes growth of and maintains accessory reproductive glands. Promotes secondary sexual character, sexual behavior and spermatogenesis. Shows assimilation action.
	Inhibin	Glycoprotein (heterodimer of and subunits)	14,000	Controls FSH release.
	Activin	Simple protein (homodimer of subunit)	Approx. 28,000	Promotes FSH release.
	Oxytocin	Peptide	1,007	Interacts with prostaglandin secreted by the endometrium to promote luteolysis.
	Relaxin	Peptide	Approx. 6,000	Involved in opening of the cervical canal, uterine contraction, maintenance of pregnancy and relaxation of pelvic symphysis.
Uterus	Prostaglandin F_2 (PGF_2)	Unsaturated fatty acid	Approx. 350	Causes uterine contraction and luteolysis.

Prepared based on Leeves, 1987, etc.

(8) Change in hormones levels in blood in the estrous cycle

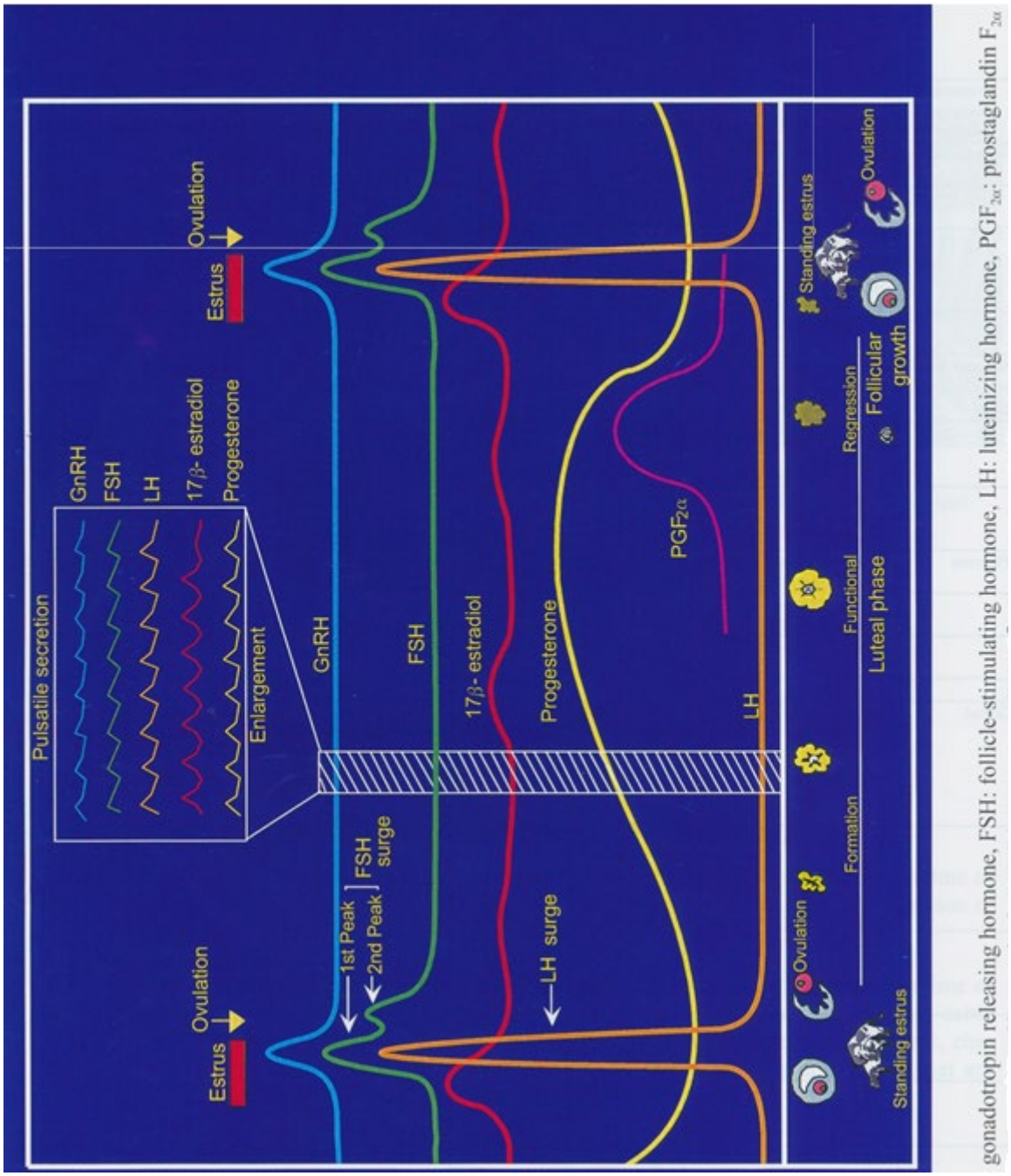

Figure 1-6 Changes in GnRH, FSH, LH, estradiol-17 β , progesterone, PGF_{20} levels in the blood in the estrous cycle

The changes in the levels of these hormones in peripheral blood during the estrous cycle are illustrated in Figure 1-6. Gonadotropic hormone releasing hormone (GnRH), produced and secreted by the hypothalamus and directly transported to the anterior lobe of the pituitary gland through the pituitary gland portal vein, is involved in the secretion by the pituitary gland of follicle stimulating hormone (FSH) and luteinizing hormone (LH).

At the time of an LH surge by the pituitary gland during the estrous phase, large quantities of FSH are also released, forming the first FSH peak. Unlike LH, FSH levels in the blood increase after ovulation as well. This second FSH peak,

which is not as high as the first one, is produced because ovarian follicles that serve as a matrix for producing inhibin are lost as a result of ovulation and the control of FSH secretion is lost.

Ovarian estrogen (E) is secreted mainly by ovarian follicles, progesterone (P4) by the corpus luteum and testosterone (T) by the testes. These steroid hormones are biosynthesized from cholesterol through the pathway shown in Figure 1-7. These steroid hormones produced by the ovary work on the uterus and control its function. P4 along with E works on the reproductive tract at the implantation stage to help prepare for implantation of embryos and plays an important role in maintaining the pregnant status. At the time of delivery, blood P4 levels decrease and E levels increase in advance of delivery to form a birth canal and thus both hormones cooperate to facilitate normal delivery.

Prostaglandin $F_{2\alpha}$ ($PGF_{2\alpha}$) is a major hormone secreted by the uterus and is secreted from the endometrium at the luteolytic stage to facilitate luteal regression. It also facilitates the shrinkage of the uterus at the time of delivery.

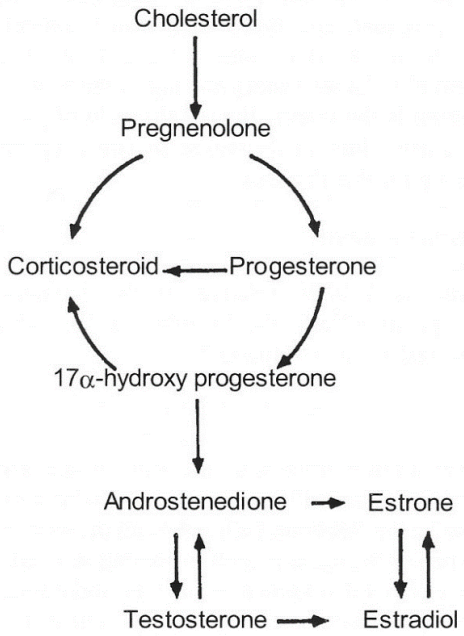

Figure 1-7 Biosynthesis pathway of sexual steroid hormones

Source: Niswender, 1974

1.2.3 Pregnancy

Pregnancy refers to the condition of cows during the period in which an emitted ovum is fertilized and develops and until a fetus is delivered.

(1) Gestation length

The gestation length of cattle is 278 ±10 days on average; that for male fetuses is 1-2 days longer than for female fetuses, that for first and second delivery of young cows is 1~2 days shorter than for fetuses of middle-aged cows and that for twins is 3-6 days shorter than for monotocous fetuses. The gestation length of buffalo is 310 ±10days on average.

(2) Pregnancy diagnosis

Identifying the pregnant status as early as possible after fertilization or mating is important in improving productivity and reproductive disorders. Changes in the mother's body resulting from pregnancy and pregnancy signs showing the presence of a fetus are used in pregnancy diagnosis and the method used in pregnancy diagnosis should ensure early, accurate and simple diagnosis and must not involve harm to the mother's body or fetus. In practice, ultrasonography, non-return method, determination of milk or blood P4 levels, palpation of the amniotic sac, fetal membrane slip, asymmetry of uterine horns, swelling of the pregnant horn and fluctuation, cervical mucus tests and palpation of the fetus and placental lobes are performed.

(3) Maintenance of the pregnancy

Important factors for the maintenance of pregnancy include the progestational proliferation of the endometrium, uterine expansion, reduction in the contraction of uterine muscle and uterine cervix closure. P4 and E are involved in all these factors. P4 levels in peripheral blood after conception are in the range of 4 8 ng/ml and the main source of P4 production is the corpus luteum throughout pregnancy. However, the P4 secretion from the corpus luteum decreases in late pregnancy and the placenta and adrenal glands make up for this decrease.

(4) Location of the fetus in the uterus

The location of the fetal body relative to the mother's body is expressed as "presentation" and "position" and the locational relationships of the fetal head and extremities are expressed as "fetal attitude".

1) Presentation

If the long axes of the fetus and the mother are parallel to each other, the presentation is referred to as "longitudinal lie "and if these axes cross, it is referred to as "transverse lie "or "oblique lie". A head presentation is when the head of the fetus faces the pelvic cavity; a breech presentation is when the breech of the fetus faces the pelvic cavity (also known as back or abdominal presentation). In cattle, about 90% of presentations are head presentations and 10% are breech presentations.

2) Position

A position indicates which of the uterine surfaces the fetal spine faces: superior, inferior or lateral. In cattle, fetuses assume the lateral position in late pregnancy.

3) Fetal habitus

Fetal habitus refers to the locational relationships of the fetal head/ neck part and fore and hind legs. During pregnancy, the fetus assumes a ventrally rounded posture according to the uterine shape. At the time of delivery, the fetus extends its fore legs, head and hind legs to pass through the tight birth canal.

1.2.4 Parturition

After the fetus develops sufficiently in the uterus to be able to live in the external environment, it is released from the mother's body. This process is referred to as delivery. Parturition is induced by the expulsive power generated by the combination of the contraction of uterine muscle, which is accompanied by labor pain, and abdominal pressure (staining) resulting from the contraction of abdominal muscle.

(1) Signs of Parturition

The pudendum is red due to congestion and soft because of swelling. The mucous plug that blocked the uterine cervix begins to soften from 2-3 days before parturition and is fluidized. It then flows into the inner part of the vagina and eventually leaks the vulva in the form of mucus similar to starch syrup. The intravaginal part of the uterus swells to the size of a fist and the external uterine orifice expands to the extent such that it allows 2-3 fingers to be inserted. Because the pelvic ligament relaxes as the parturition approaches, both sides of the tail head are depressed so that the tail head looks elevated. This is particularly apparent 2-3 days before parturition.

The swelling of the udder becomes increasingly noticeable as the delivery time approaches and trial milking may show that the initial relatively clear honey-like secretion changes to an opaque colostrum.

As parturition approaches, pregnant cows show uneasiness, look at their abdomen frequently, wander about inside the cow shed restlessly, repeat lying and standing up and scratch the floor with their fore legs. They urinate more frequently and leak urine sporadically.

(2) Parturition process

The birth canal is a route through which the fetus passes at the time of parturition and consists of the bony birth canal and soft birth canal. The bony birth canal is a pelvic cavity that is surrounded by the pelvis consisting of the hipbone, sacrum and coccygeal bone. The joints of these bones are fixed with ligaments but they relax by the action of E and relaxin as the delivery time approaches, resulting in an enlarged pelvis. The soft birth canal consists of the uterine cervix, vagina and vulva and is enlarged at the time delivery.

A virtual line along which the fetal vertical axis may pass the pelvic cavity is referred to as the pelvic

The fetus must be drawn along this pelvic axis. The pelvic axis of cattle is undulated vertically Figure l-8; the fetus must be drawn upward until the fetal head emerges completely, horizontally until the chest emerges and downward until the full body emerges.

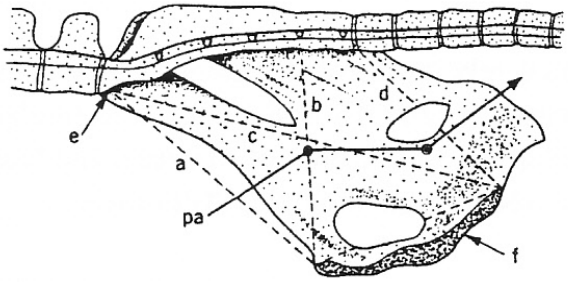

pa: Pelvic axis
a: True conjugate of the pelvic in let (anteroposterior diameter)
b: Vertical line of the pelvis
c: Oblique symphysis of the pelvis
d: True conjugate of the pelvic outlet

Figure 1-8 Bovine pelvis

Source: Stoss, modified by S. Hoshi and Y. Yamauchi, 1982

The delivery process is divided into the opening period (1st stage), expulsion period (2nd stage) and the afterbirth period (3rd stage). During the opening period, the birth canal is formed to prepare for delivery. In the expulsion period, the opening of the uterus is fully open and the fetus is delivered. The afterbirth period refers to a postpartum period until the afterbirth is discharged.

During the opening period, the fetal sac enters the cervical canal in advance of the fetus to dilate it. Opening labor pains last for a period of 3-6 hours, during which the fetus is more active and changes its position from lateral to superior positions.

The expulsion period starts with contraction or straining of the abdominal wall. Straining occurs 8-10 times every time the uterus contracts. The allantoic chorion ruptures since it is attached to the placenta and cannot move with the fetus. The amnion is relatively mobile so it is exposed outside the vulva and forms the foot sac. The rupture of the allantois is referred to as the first rupture of bag and that of the amnion as the second rupture of bag. Delivery is smooth once the fetal chest passes the vulva. The newborn's umbilical cord may be spontaneously broken at birth but it is not cut before the mother moves in some cases.

During the afterbirth period, contraction of the abdominal wall almost subsides but uterine contraction still continues. The contraction force is reduced but its frequency is increased. The fetal placenta is exfoliated and discharged as a result of afterbirth labor. It is normally discharged in 6-8 hours but may not be discharged in a fixed time. In these cases it is referred to as the retained placenta, which occurs frequently in cattle because of cotyledonary placenta.

(3) Major hormones involved in parturition

Parturition is induced by hormonal changes in the fetal hypothalamo pituitary-adrenal system, as demonstrated by a study of sheep. As the parturition time approaches, adrenocorticotropic hormone (ACTH) is probably secreted by the fetal pituitary gland and in response to this, a large quantity of cortisol is secreted by the fetal adrenal glands. This cortisol acts on the placenta to secrete a large quantity of estrogen (E) and to reduce the secretion of progesterone (P4). Increased estrogen stimulates the production and secretion of prostaglandin $F_{2\alpha}$ ($PGF_{2\alpha}$) by the placenta and also act on the maternal uterus to produce and secrete more $PGF_{2\alpha}$. In addition, estrogen and the relaxin secreted by the ovary help relax the birth canal. As a result of reduced P4 secretion and increased E secretion, the proportion of P4 and E levels in the maternal blood changes, the uterine muscle is more sensitive to oxytocin (OT) and contraction starts. After the start of parturition, the fetus stimulates the cervical canal wall to dilate and also stimulates OT secretion by the nervous lobe of hypophysis. As a result, the fetus is given birth. These mechanisms demonstrated in sheep are considered to be common to cattle.

(4) Physiology of puerperium

After parturition, involved organs such as the uterus try to reverse the changes produced by the effects of pregnancy and parturition and restore to their original state. This process is referred to as puerperium and normally lasts for 3-4 weeks. Involved in the restoration of reproductive organs are oxytocin (OT) and prostaglandin (PG). The PG level rapidly increases at delivery, reaches its peak within 3 days of parturition and returns to the baseline level in about 15 days. Uterine contraction disappears in 4 days and the pregnant horn is reduced to half in 5 days in breadth and in 15 days in length. The cervical canal tightens to the extent that inserting a hand is difficult in a day and narrows to the extent that it only allows two fingers to be inserted in 4 days. Liquid excretion, or lochia, is the most abundant between 2 and 3 days after parturition and disappears within 14-18 days of parturition. Uterine restoration in terms of size (uterine involution) is completed in 25 days or more but the normalization of the intrauterine bacterial flora may take 40-45 days.

(5) Return of estrus after parturition

The ovary is static immediately after deliver, however ovarian follicles start growing in about a week at the earliest and the ovary is activated quickly as soon as ten days have passed. The first ovulation takes place in about 2 weeks after

parturition at the earliest and about 20 days in most cases. Development of ovarian follicles is delayed in nursing cows compared to milking cows and the first ovulation occurs earlier in cows that take in more energy.

The mean number of days between parturition and the first estrus varies significantly from report to report, however it is estimated to be 20-70 days and is greatly affected by the age, parity, season and nutritional and lactation conditions. It is known to increase in high-lactation cows as well as in cows that suffer abnormal parturition and diseases.

The estrus at the time of the first ovulation after parturition is dull in nature and does not show estrous signs in many cases. However, the incidence of dull estrous is lower in cows that have experienced ovulation more times. The corpus luteum that is formed after the first postpartum ovulation generally grows poorly and is short-lived.

1.3 Latest progress in the studies of mechanisms of controlling reproductive function

1.3.1 Changes in hormone concept

Hormones have been conventionally considered to be chemical messengers that are secreted by endocrine organs and transported to remote target organs to transmit information. However, recent advances in research have revealed various substances that are difficult to differentiate from hormones. Studies of the mode of action have also demonstrated that a certain hormone not only exhibits an endocrine action but also plays an important role in facilitating reproductive function by means of paracrine and autocrine action and that neurotransmitters and immune-related substances that have not been considered hormones are involved in reproductive function (see next section). These substances include insulin-like growth factor (IGF), epidermal growth factor (EGF), transforming growth factor (TGF), nerve growth factor (NGF), immune-related cytokines such as interleukin 1 (IL-1) and neuropeptides such as dopamine, encephalin and substance-P. These substances are now included as hormones and referred to as new hormones compared to conventional hormones, which are called classic hormones.

1.3.2 Hormonal mode of action

Recent advances in research have shown that hormones can act locally on cells adjacent to the hormone-secreting cells or, in some cases on the hormone-secreting cells themselves instead of being transported to remote locations. The mode of action of hormones is shown in Figure 1-9 (P.12). Signal messengers with paracrine and autocrine action that have not been considered hormones are now included as hormones.

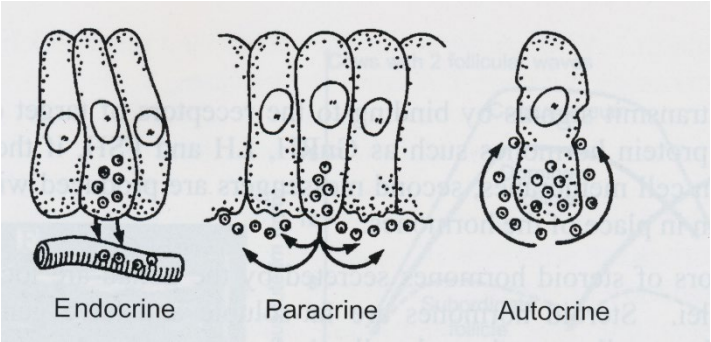

Figure 1-9 Mode of action of hormones Source: Kan Miyake, 1995

1.3.3 Feedback mechanisms

Reproductive function is controlled by hormones secreted by endocrine organs such as the hypothalamus, pituitary gland and gonad. An assumption is made that the mechanism depends on the hypothalamus-hypophyseal-gonadal axis and the hormones secreted by higher organs control the functions of lower organs. However, research shows that hormones

secreted by lower organs may control the functions of higher organs and these mechanisms are referred to as feedback mechanisms. Feedback mechanisms include promotive (positive) and suppressive (negative) ones (Figure 1-10).

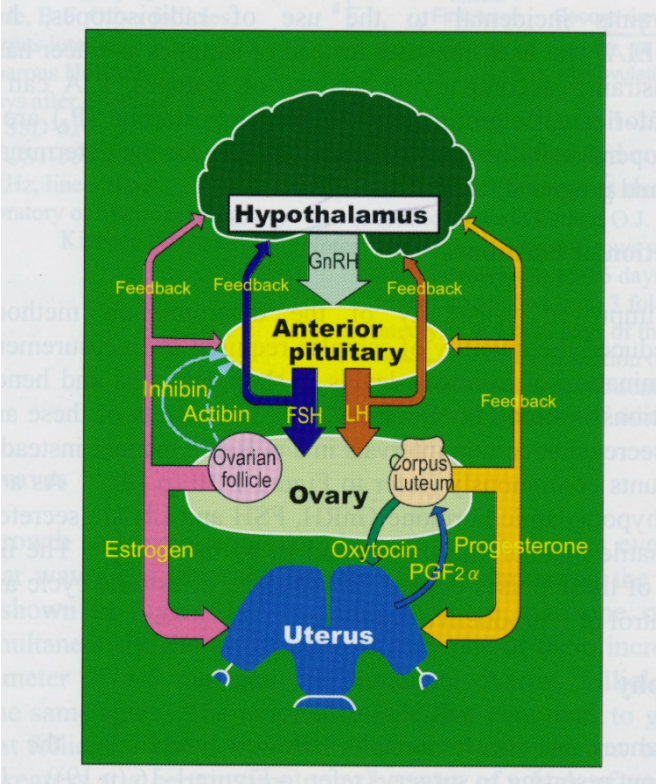

Figure 1-10 Relation between the mastitis for the secretion of major reproductive hormones and their target organs

1.3.4 Receptors

Hormones transmit signals by binding to the receptors of target cells. The peptide or protein hormones are such as GnRH, LH and FSH. These hormones bind to receptors on cell membranes, second messengers are produced within cells and control cell function in place of the hormones.

The receptors of steroid hormones secreted by the gonad are located on cytoplasm or within nuclei. Steroid hormones are fat-soluble and have generally low molecular weight so they easily pass through cell membranes and bind to intracellular receptors to transmit signals. Unlike peptide hormones, steroid hormones do not need second messengers.

Reproductive functional disorders have been attributed to lack of hormones but the latest studies show that these disorders include some cases of hormone irresponsiveness resulting from abnormal receptors and abnormal action after the binding of hormones and receptors.

1.3.5 Ultrasonography

Dramatic advances in ultrasonography allowed visualizing the organ and tissue structures without resorting to surgery (refer to Figure 1-11) . Using this method, morphological changes in organs such as the development of the ovarian follicles and formation and regression of the corpus luteum can be visualized. Studies of morphological changes in the ovary using this method revealed that ovarian follicles are present even in the ovary of cows in the luteal phase and alternate between growth and regression regularly. This process is referred to as follicular waves.

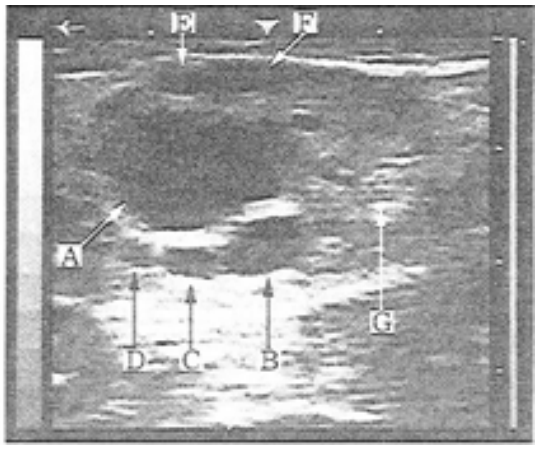

A: Dominant follicle

B-F: Other follicles

G: Corpus luteum

Material cow: Multiparous Holstein

Estrous cycle: at 6 days after ovulation (Day 6)

Equipment: Aloka SSD 610

Probe: Aloka UST 556T-7.5 (7.5 MHz, linear type)

(Laboratory of Theriogenology, Kitasato University)

Figure 1-11 View of an ovarian follicle and corpus luteum of a cow in the estrous cycle using ultrasonography

1.3.6 Follicular waves

Follicular growth and regression take place in bovine ovaries even in the luteal phase and follicular waves are generally repeated 2-3 times during the estrous cycle. This process is shown in Figure 1-12. Although more than one ovarian follicle - starts growing simultaneously, the growth rate of only one of them increases rapidly when it reach a diameter of 4-5 mm and the remaining ovarian follicles stop growing and remain at the same size. The ovarian follicle that continues to grow is referred to as the dominant follicle. The dominant follicle continues to grow but in the luteal phase it begins to regress at a certain time point because of a lack of an LH surge and hence ovulation occurs due to high blood P4 levels. If this first-wave dominant follicle starts regression, the second-wave follicles begin to grow and follow the same process. If the growth of the second-wave dominant follicle falls in the estrous phase, there is an LH surge and resultant ovulation take place. If the second-wave dominant follicle regresses rather than ovulates, then the third wave occurs and the third-wave dominant follicle ovulates. With cattle, follicular waves take place 2-3 times during an estrous cycle in most cases and once or 4 times in rare cases.

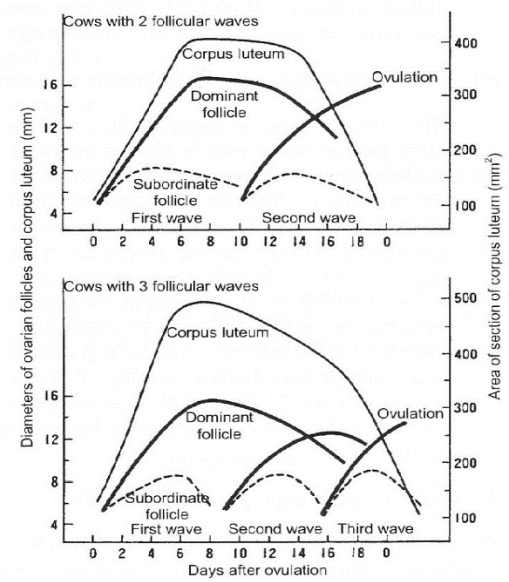

Source: Modification of Ginther, O.J. et al., 1989, 1994

Note: The corpus luteum of cows with 2 follicular waves starts luteolysis at 15-16 days of the estrous cycle while that of cows with 3 follicular waves starts luteolysis at 18-20 days of the estrous cycle.

_____ Area of section of corpus luteum

_____ Diameter of dominant follicle

_ _ _ _ _ Diameter of subordinate follicle

Figure 1-12 Fate of ovarian follicles and corpus luteum in cows with 2 or 3 follicular waves during an estrous cycle

1.3.7 Discovery of new hormones, inhibin and activin

The follicular fluid of mature follicles of cows has been found to contain a relatively large proportion of inhibin that inhibits FSH secretion by the pituitary gland. This finding indicates that unlike LH secretion, FSH secretion is dually controlled by GnRH and inhibin. Inhibin is a glycoprotein hormone with a molecular weight of about 32,000 and also a heterogeneous dimer consisting of α and β subunits. Inhibin is produced mainly by the granulosa cells of the ovarian follicle in cows and the Sertoli's cells of the testis in bulls and is transported via the blood flow to the pituitary gland, where it inhibits FSH secretion by the pituitary gland. Studies of inhibin revealed the presence of activin having a physiological function opposite inhibin, a function to promote FSH secretion. Activin is produced by the same organs as inhibin. Activin is a homogeneous dimer consisting of the same subunit as inhibin with a molecular weight of about 24,000 and plays an important role in cell differentiation as well. It is bound to follistatin in the blood so that it does not induce the pituitary gland to release FSH.

Chapter 2 Definition and types of reproductive disorders

2.1 Definition of reproductive disorders

A reproductive disorder is defined as a status in which the reproductive function of a female or male animal is temporarily or persistently suspended or disturbed and abnormal calves are produced. Causal factors include inappropriate feeding environments and methods, genetic defects, nutritional disorders, systemic diseases, reproductive anomalies and diseases, abnormal secretion of various hormones and inappropriate breeding management of reproductive disorders.

One type that leads to a failure of conception due to the anomalies and diseases of the reproductive organs is sometimes referred to as sterility and another type that leads to conception but results in an embryonic or fetal death and subsequent absorption and abortion is referred to as infertility.

2.2 Manifestations of reproductive disorders and reproductive diseases

2.2.1 A case in which an animal with anomalies of the ovary or uterus develops abnormal estrous conditions such as anestrus and fails to mate even if it has attained 12 months old or 40 days have passed since the last delivery

(1) Freemartin

In bovine unlike-sexed twin and multiple pregnancy, about 92% of female fetuses fail to have normal sexual differentiation and are likely to have anomalies of the reproductive organs that lead to absolute sterility. This sterile cow is referred to as freemartin.

The cause has not yet been clarified, however, one suggested reason is that the blood vessels of female fetal membranes are anastomosed with the blood vessels of male fetal membranes in the early embryonal phase to produce an exchange of blood so that the sex-determining region Y (SRY) deriving from the male, which masculinizes reproductive organs, masculinizes the ovarian primordium of the undifferentiated female fetus and induces the secretion of androgen.

Findings in clinical diagnosis include the length of the vagina being 1/3 the normal length or less, hypertrophy of the clitoris and rough and long pubic hair. In a vaginal examination of calves, a test tube 2 cm in diameter and 20 cm long can be inserted 12-18 cm into the vagina in normal calves but only 8- 10 cm into the vaginal vestibule in freemartins since they lack a vagina. By rectal palpation, a hard cylinder/ cone-shaped object is normally felt 5- 10 cm in front of the vaginal vestibule, but the cervical canal, uterus and ovary are not palpable. There is no cure and conception is not possible.

(2) Ovarian functional disorder

A state in which nulliparous cattle or buffalo within 12 months of birth (for animals reared in developed countries), 24 to 30 months of birth (for animals reared in tropical developing countries where animal growth is slow) and 40 days after delivery (for multiparous cattle or buffalo) develop no ovarian follicles or ovarian follicles develop to some extent but repeat atresia and regression without ovulating, resulting in continued anestrus. This disorder is divided into ovarian hypoplasia, ovarian quiescence and ovarian atrophy. These disorders are closely related with nutritious condition of animals. Nutritious conditions of animals need to be evaluated with BCS and adjust feed to improve nutritious condition, if necessary.

1) Ovarian hypoplasia

Ovarian hypoplasia is a case that nulliparous cattle or buffalo do not show estrus sign. Both the right and left ovaries grow insufficiently and are extremely small, flat and inelastic. Growth of the uterus is inadequate.

2) Ovarian quiescence

Ovarian quiescence is a case that sexually matured nulliparous cattle or buffalo do not show estrus sing or a case multiparous cattle or buffalo do not show estrus sign even after 2 months or more from last parturition. The shape of the ovary is normal; however, the ovarian follicles do not grow or grow to some extent but repeat atresia and regression without ovulating. The uterus is small and inelastic in some cases and is normal in shape in some cases. In multiparous cow, postpartum uterine involution is delayed in many cases.

3) Ovarian atrophy

Ovarian atrophy is a case multiparous cattle or buffalo that do not become old-age do not show estrus sign. Both the right and left ovaries are dwarfed, indurated and flat with smooth or wrinkled surfaces and they neither form ovarian follicles or corpus nor ovulate. The uterus is small and inelastic.

The direct cause of this disorder is a reduction in the ability of the anterior lobe of the hypophysis to secrete gonadotropins (GTH), i.e. follicle-stimulating hormone (FSH) and luteinizing hormone (LH), and this condition is related to a reduction in gonadotropin-releasing hormone (GnRH) secretion due to the suppressed function of the hypothalamus. The predisposing causes include inappropriate feeding and management such as, in particular, qualitative and quantitative deficiencies of feed and an inferior feeding environment, and in nulliparous cows, parasitic diseases of the alimentary canal during the raising stage and in multiparous cows, systemic wasting diseases during the perinatal period. Genetic factors are also involved in ovarian hypoplasia in nulliparous cow.

Diagnosis should be based on rectal palpation and if the first diagnosis fails, an additional examination should be performed 7-14 days afterwards. Diagnosis should be made by confirming that nothing has changed compared to the findings in the previous examination of the right and left ovaries.

If poor health is caused by inappropriate feeding and inferior feeding environments, farmers should be instructed to improve these predisposing factors to eliminate causes. If systemic diseases are causing the disorder, these diseases should be treated, and normal nutritional and health conditions restored. Hormone preparations should be administered after or in parallel with these procedures. Complicating uterine diseases should be treated.

Efficacy of the treatment with hormone formulations depends on the stage of the follicular wave at the time of administration. Thus, if rectal palpation reveals a growing ovarian follicle 10-15 mm in diameter in the ovary, 1,500-3,000 international units (IU) of human chorionic gonadotropin (HCG) or 100 μg fertirelin acetate or buserelin acetate at a dosage of 10-20 μg as buserelin, both gonadotropin-releasing hormone analogues (GnRH analogues), should be administered once by intramuscular injection for the purpose of inducing follicular maturation and ovulation and forming corpus luteum afterwards. The interval between the first and second ovulation after hormone therapy is usually in the range of 8-15 days, which is shorter than normal. Therefore, farmers should be instructed to observe estrous signs 8, 20 as well as 30 days after treatment.

If no growing ovarian follicle is present in the ovary, intramuscular or subcutaneous injection of 500-1,000 IU of pregnant mare serum gonadotropin (PMSG) or simultaneous injection of 500-1,000 IU each of PMSG and hCG should be administered once for the purpose of inducing follicular growth, maturation and ovulation and forming

corpus luteum. In addition, intravenous or intramuscular injection of 200-400 Rab.U of bovine anterior pituitary gonadotropin (APG) or intravenous injection of 20-40 A.U. of swine anterior pituitary follicle-stimulating hormone (APFSH) should be administered once. Mating with a cow with estrus that appears several days after PMSG administration may lead to a multiple pregnancy due to superovulation.

In addition, for the purpose of normalizing GTH secretion from the anterior lobe of the hypophysis in 'cow' with ovarian quiescence, controlled internal drug release device (CIDR) and progesterone releasing intravaginal device (PRID: capsule containing estradiol-17β),which are indwelling types of luteal hormone sustained-release preparation, were inserted into the vagina and maintained in the same position for 12 days with good results.

A normal estrous cycle after treatment indicates that the treatment was successful. In spite of treatment with hormone preparations, some ovarian follicles fail to ovulate and fall into atresia and regression and some ovaries fall into quiescence even if the corpus luteum is formed after ovulation. Thus, if rectal palpation for luteal formation 7-14 days after treatment reveals the absence of efficacy, the type and dosage schedule of hormone preparations should be reconsidered. If repeated treatment of ovarian hypoplasia in nulliparous cow by this method has no effect on the ovary, then the prognosis is diagnosed as poor.

(3) Ovarian cyst

Ovarian cyst refers to a condition in which an ovarian follicle grows to more than 2.5 cm in diameter without ovulating and is divided into follicular cyst and luteal cyst. The frequency of follicular cyst is higher than that of luteal cyst.

1) Follicular cyst

An ovarian follicle grows to more than 2.5 cm in diameter without ovulating, persists for a long time and then regresses. This process is repeated.

Because this disorder occurs in obesity due to oversupply of concentrate feed and deficiency of exercise and in poor nutrition due to qualitative and quantitative deficiency of feed. Stress from inappropriate feed types and feeding management as well as the oversupply of feed containing estrogen-like materials and genetic factors such as predisposition to follicular cyst are known to be involved in the disorder.

The direct cause of the disorder is abnormal secretion of GTH due to reduced function of the anterior lobe of the hypopbysi, or transient mass release of LH that induces ovulation, that leads to a failure of LH surge. This indicates that it may be caused by an abnormality in the LH releasing mechanism resulting from decreased sensitivity to a rise in estradiol concentrations in the hypothalamus-anterior lobe of the hypophysis system. Another mechanism is that progesterone secreted by the adrenal gland acts on the higher-level organ hypothalamus to suppress the release of GnRH.

Symptoms include 1) nymphomania in which estrous signs appear constantly or frequently and 2) sexuality increases or a sign in which estrous signs appear irregularly, but 3) estrous signs are absent in many cases. In the case of a long-term process, the both sides of the tail bead are depressed, and the tail head is elevated due to loosened Lig. Sacrotuberale Latum.

The disorder is diagnosed if one or more large-size ovarian follicles 2.5 cm or more in diameter are present in one or bilateral ovaries by rectal palpation (Photograph 2-1 (p.42)), these follicles increase in size or remain at the same size at the time of reexamination 7-14 days later and the corpus luteum is absent. Ovaries with growing ovarian follicles are swollen

and contractible and those with degenerating ovarian follicles are relaxed. The disorder is complicated by endometritis in many cases.

Care must be taken because there is an ovarian condition similar to this disorder in which a luteal cyst, cystic corpus luteum, a large-size ovarian follicle and corpus luteum (a large-size ovarian follicle and a normal growing ovarian follicle in the estrous) are coexistent as seen in Table 2-1 and Photograph 2-2 to 2-6 (p. 42). If differentiating between these conditions is difficult, reexamination should be performed 7 - 14 days later. Diagnosis of follicular cyst is made if ultrasonography reveals that no luteal layers are present near the follicular fluid of the ovary or a large-size ovarian follicle and if progesterone concentrations are 5 ng/ml or lower in whole milk and 1 ng/ml or lower in plasma and skimmed milk.

Various ovarian cyst are shown in the table 2-1. It is difficult to differentiate follicular cyst and luteal cyst. First, suspect a case as a follicular cyst and inject HCG. If a case is follicular cyst and endocrinological characteristics is 'a', i.e. granulosa layer present in cyst, luteinization occurs with HCG injection. If no effect is observed through rectal palpation 10 days after HCG injection, suspect the case as luteal cyst. Inject PGF_{2a} to regress corpus luteum in case of luteal cyst. When cattle or buffalo is pregnant, abortion happens with PGF_{2a} injection. Injection, therefore, is better to be given after confirmation of unpregnant through rectal palpation.

Table 2-1 Differences in secretion of steroidal hormones in ovarian cysts and similar forms

Classification		Schematic section views of the ovary (left and right)	Endocrinological characteristics
Ovarian cyst	Follicular cyst (FC)		a: high levels of OE_2 and BE_2, granulosa layer present or growing b: low levels of OE_2 and BE_2, granulosa layer degenerated or lost c: intermediate type of a and b
Ovarian cyst	Luteal cyst (LC)	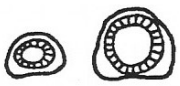	OE_2 low being expressed in pg/ml and OP high being expressed in µg/ml BP at the level of 1-3 ng/ml (luteal layer present in cystic cavity)
Cystic corpus luteum (CCL)			OE_2 mostly low being expressed in pg/ml. OP high being expressed in µg/ml, BP at the luteal phase level being 3-10 ng/ml, lower than normal on average (OE_2 and OP indicate levels in the luteal cavity fluid)
Coexistence of large-size ovarian follicles and corpus luteum (FCL)			OE_2 mostly low being expressed in pg/ml OP mostly at 100-800 ng/ml levels BP at the luteal phase level being 3-10 ng/ml
Estrus (ES)			Similar to follicular cyst (FC)

(Cited from Hoshino)

Notes

1: OE2, OP, BE2 and BP represent estradiol and progesterone levels in cystic follicular cavity fluid and peripheral blood, respectively.

2: Steroidal hormone levels were determined by radioimmunoassay.

O:overy, B:blood

In some cases within 40 days postpartum in which an ovarian follicle that grew to 2.5 cm in diameter or larger persists for some time and undergoes regression to atresia while another ovarian follicle that grew anew ovulates, the disorder may be healed spontaneously but reexamination should be performed 7-14 days later and the disease treated as needed.

If the cause of this disorder is related to feeding and management, and especially inappropriate feeding, farmers should be instructed to improve such conditions. In addition, 100-200 µg of fertirelin acetate or buserelin acetate at a dose of 10-20 µg as buserelin, both GnRH analogues, should be administrated once by intramuscular injection for the purpose of inducing the anterior lobe of hypophysis to cause endogenous LH surge. 5, 00-10, 00 IU of hCG should also be administered once by subcutaneous or instramuscular injection to supplement GTH that has LH action. If these treatments fail,intravenous or intramuscular injection of 200-400 Rab.U bovine APG or intravenous injection of 20-40 A.U. swine APFSH or subcutaneous or intramuscular injection of 40-60 A.U. swine APFSH should be administered once. Administration of these hormone preparations when a new ovarian follicle grows in the follicular wave of an ovarian follicle coexisting with the cystic follicle induces ovulation and subsequent luteinization so the efficacy of the hormone therapy can be enhanced. Care must be taken when using hCG, bovine APG and swine APFSH preparations because antihormones are produced in the body and reduce therapeutic effect if they are used repeatedly.

For the purpose of normalizing the release of GTH, especially LH, from the anterior lobe of the hypophysis, CIDR was inserted into the vagina and retained at the same position for 12 days with good results. If rectal palpation performed 7-14 days after treatment with the aforementioned hormone preparations reveals luteinization in the ovary, then the treatment is diagnosed as effective.

The responses of the ovary to treatment include one in which an ovarian follicle less than 2.0 cm in diameter coexisting with the cystic ovarian follicle ovulates and forms the corpus luteum, one in which the cystic ovarian follicle ruptures and the corpus luteum is formed afterwards and one in which the cystic ovarian follicle degenerates to atretic corpus luteum or undergoes retrogression to atresia. The response in which the formed corpus luteum regresses within 25 days of administration, estrus emerges as ovarian follicles develop and normal corpus luteum is formed after ovulation is diagnosed as healed.

Farmers should be informed beforehand that there are some cases in estrus appears around 10 days after administration and an estrous cycle duration of about 10 days is repeated. At the time of the first estrous around 20 days after treatment, findings suggest as if the disorder is not yet healed beca1 liquid content of the cystic ovarian follicle that was present in the ovary at the time of treatment remains as is without being absorbed. However, if clear appears and new ovarian follicles 1.5-2.0 cm in diameter are present in the insemination should be performed without hesitation.

If treatment fails or the disorder recurs, the type of hormone preparation and dosage schedule should be reconsidered for additional treatment. If the disorder recurs in spite of various treatments mentioned above, the case should be judged as having no chance of healing.

2) Luteal cyst

A state in which ovarian follicles grow to 2.5 cm or larger but do not ovulate or the entire formed cystic follicle walls luteinizes and the cystic follicle forms an internal cavity that retains fluid. Once formed, a luteal cyst continues to exit for a long time and suppresses the growth of normal ovarian follicles so an anestrous state persists.

The disorder is often complicated by follicular cysts so its diagnosis should follow that of follicular cysts. Differentiation from follicular cysts or cystic corpus luteum formed after ovulation and from normal corpus luteum is often difficult if rectal palpation reveals luteal layers on part or the entire cystic walls (Photograph 2 2&3 (p.42)) and thick luteal layers, respectively. The diagnosis of this disorder is made ultrasonography reveals the presence of luteal layers around the cavity contain fluid or the determination of progesterone levels in milk or plasma reveals that the level in whole milk and that in plasma and skimmed milk are more than 5 ng and 1 ng/ml, respectively, and reexamination 14-20 days later reveals no changes.

The disorder is likely to be confused with cystic corpus luteum, however, differentiation is possible because of the fact that cystic corpus luteum is formed after ovulation so that it has processus (photograph 2-4 &5 (p.42)) and maintain a normal estrous cycle. Care must be taken, however, because rectal palpation may fail to detect the processus of a cystic corpus luteum with the major axis of at least 3.0 cm.

As a treatment for luteal cyst, either one of prostaglandin (PG) $F_{2\alpha}$ preparations, 12-15 mg of dinoprost or tromethamine dinoprost at a dose of 15-25 mg dinoprost, or one of $PGF_{2\alpha}$ analogues, i.e. 500 µg of cloprostenol or 5 mg etiproston tromethamine, should be administered once by intramuscular injection Alternatively, 1 mg of fenprostalene should be administered by subcutaneous injection to facilitate the regression of the luteal layers of the cystic walls and the growth of ovarian follicles.

If ovarian follicles develop within 10 days of treatment, followed by the occurrence of estrus and ovulation, and a normal corpus luteum is subsequently formed, the case is diagnosed as healed. Care must be taken when making a diagnosis because cavity fluid sometimes remains after the disappearance of the luteal layers of a luteal cyst appearing as if it shifted into a follicular cyst.

(4) Silent heat

A clinical condition in which in spite of the normal ovarian cycle, i.e. periodic follicular growth, ovulation and luteinization, estrus does not occur normally will regress the corpus luteum and follicular growth. Because of unclear estrous signs, the condition disturbs mating and causes a reproductive disorder but conception by insemination is possible by identifying the optimum time for insemination from information about internal estrous signs and the follicular growth status obtained from vaginal and rectal inspections.

Possible causes include abnormal secretion of GTH, quantitative imbalance between estrogen and progesterone, the high threshold level of sex hormones for nervous excitation involved in the expression of estrous behavior and psychological factors, although the direct cause is not well understood. Silent heat frequently occurs in cows with high milk yield, fat cows, cows raised in cowsheds under unfavorable feeding management conditions, low-class cows in a herd and cows with algetic diseases of the hoof.

If rectal palpation reveals that internal estrous signs are clear with mature ovarian follicles present in the ovary but they ovulate without external estrous signs and if the corpus luteum is present in the ovary, a reexamination 7- 14 days later reveals changes in the location and shape of the corpus luteum and external estrous signs are not present during this period, then the case is diagnosed as silent heat. In making a diagnosis, the fact that many cases of the first and second postpartum ovulation in the ovarian cycle are quiet ovulation and that there are many cases in which careless farmers overlook external estrous signs should be noted and care must be taken as to the differentiation between a retained corpus luteum and pregnancy.

To treat a case in which rectal palpation reveals the corpus luteum that was formed after silent heat, either

one of $PGF_{2\alpha}$ preparations, i.e. 12-15 mg of dinoprost or tromethamine dinoprost at a dose of 15-25 mg as dinoprost, or one of the $PGF_{2\alpha}$ analogues, i.e. 500 µg of cloprostenol or 5 mg of etiproston tromethamine, should be administered once by intramuscular injection. Alternatively, 1 mg of fenprostalene should be administered by subcutaneous injection. Studies showed that the administration of a GnRH analogue, fertirelin acetate, at a dose of 100 µg 54 hours after treatment with the aforementioned drugs followed by insemination 18-24 hours later generally provided satisfactory conception rates. Intramuscular injection of 2-5 mg of estradiol benzoate, a follicular hormone preparation, in the cases with a regressive corpus luteum and growing ovarian follicles induced estrous signs. An infusion of 30-50ml of povidone iodine solution (containing 20 mg of povidone iodine or 2 mg of effective iodine per milliliter) into the uterus in the luteal phase induced clear estrous signs 6-11 days later. In addition, to normalize endocrine abnormalities by adjusting blood progesterone levels, CIDR was inserted into the vagina and retained in the same position for 7 days with good results.

Insemination should be performed if estrus occurs after treatment. In some cows with poor nutritional and health conditions or algetic diseases of the hoof, quiet ovulation occurs after treatment, development of ovarian follicles that occurs simultaneously with luteolysis is quite late or ovarian follicles undergo regression to atresia without ovulation and shift to ovarian quiescence. Thus, causal factors must be improved before treatment.

(5) Retained corpus luteum (persistent corpus luteum)

A clinical condition in which the functioning corpus luteum continues to exist for a longer period than normal in the estrous cycle in the absence of pregnancy. Progesterone secreted by the corpus luteum suppresses the growth of ovarian follicles resulting in an extended period of anestrus. PGF_{2a} injection is highly effective for retained corpus luteum. PGF_{2a}, however, cause abortion if it is injected when cattle or buffalo are pregnant. Confirmation of pregnancy before injection is important.

There are two possible mechanisms for the disorder. One mechanism is that the presence of foreign materials such as a mummified fetus, pus and mucus in the uterus or abnormalities in the endometrium such as chronic inflammation inhibit the production and/or release of luteolytic factors by the uterus. Another is abnormal secretion of GTH from the anterior lobe of the hypophysis and this mechanism may be involved in the disorder of the type occasionally seen in high-lactation cows that is not accompanied by uterine abnormalities.

Diagnosis should be made by confirming that rectal palpation reveals the corpus luteum in the ovary and a reexamination 10- 14 days later reveals no changes in the location or shape of the corpus luteum. Diagnosis of the disorder is also made if the progesterone level does not decrease to lower than 5 ng/ml and 1 ng/ml in whole milk and plasma and skimmed milk, respectively, in the examination of progesterone levels in milk or blood that is performed continuously at 3 to 4-day intervals for more than 25 days.

Care must be taken because there may be foreign matter in the uterus. If the presence of mucous matter in the uterus is suspected, ultrasonography should be performed and as required, a sample of the content of the uterus should be taken via the cervical canal for the study of its properties. This must be distinguished from the early stage of pregnancy.

As a treatment for the disorder, either one of $PGF_{2\alpha}$ preparations, i.e. 12-15 mg of dinoprost or tromethamine dinoprost at a dose of 15-25 mg as dinoprost, or one of $PGF_{2\alpha}$ analogues, i.e. 500 µg of cloprostenol or 5 mg of etiproston tromethamine, should be administered once by intramuscular injection to facilitate luteolysis and growth of ovarian follicles. Alternatively, 1 mg of fenprostalene should be administered by subcutaneous injection. The

corpus luteum was enucleated with fingers through the rectal walls in an old-fashioned treatment for the disorder, however, this method must not be employed because ovarian function may be impaired due to bleeding, and occasionally lethal bleeding, from the ovary and adhesions near the ovary. Foreign matter in the uterus must be removed.

If luteolysis occurs within 10 days of treatment with the above-mentioned drugs and ovarian follicles develop and ovulate followed by the formation of a new corpusluteum and a normal estrous cycle, then the case is diagnosed as healed. Treatment must be made if the corpus luteum that was present at the time of treatment is still present 10 days later. Care must be taken because a shift to ovarian quiescence and an ovarian cyst may occur after treatment or a fluid such as mucus may be retained within the uterus and result in recurrence of the disease.

(6) Pyometra

A condition in which pus or purulent exudate collects in the uterine cavity. This occurs because purulent exudate resulting from purulent endometritis is not expelled into the vagina because the cervical canal is closed. The disease often follows delayed recovery of the uterus due to dystocia and retained placenta in the perinatal period and it sometimes results from infection by bacteria such as *Actinomyces pyogenes* and protozoans such as *Trichomonas fetus* that enter the uterus at the time of insemination of a pregnant cow showing estrous.

Purulent exudate that collected in the uterine cavity suppresses the production of luteolytic factors by the uterus and causes retained corpus luteum resulting in an extended anestrous period. A vaginal examination often reveals dry vaginal mucous membranes and a closed external uterine orifice presenting findings similar to the pregnancy period. Rectal palpation reveals that the uterus is expanded, subsiding into the abdominal cavity, presenting fluctuations and has no contractibility with thin uterine walls. The uterus feels similar to the one in the second to third month of pregnancy in many cases so differentiation from pregnancy is necessary. If a differential diagnosis fails, reexamination must be performed a few weeks later. Changes in the uterus according to the number of days after mating are observed in the case of pregnancy but not in the case of pyometra. Systemic symptoms and changes in blood properties are absent if a large amount of pus accumulates in the uterus. Ultrasonography reveals the pus in the spherically enlarged uterine cavity as a hypoechoic image but it does not show the presence of the fetus or conceptus in that area.

In case of pyometra, corpus luteum can always be found. Check corpus luteum. Fetal membrane slipping cannot be detected. PGF_{2a} injection is highly effective. Penicillin injection after intrauterineirrigation is effective, as well (As for penicillin injection, refer to 2.2.4. Endometritis). It is better not to inject iodine solution since uterine wall is thick in case of pyometra.

As a treatment for the disorder, either one of $PGF_{2\alpha}$ preparations, i.e. 12-15 mg of dinoprost or tromethamine dinoprost at a dose of 15-25 mg as dinoprost, or one of $PGF_{2\alpha}$ analogues, i.e. 500 μg of cloprostenol or 5 mg of etiproston tromethamine, should be administered once by intramuscular injection to facilitate luteolysis and the growth of ovarian follicles. Alternatively, 1 mg of fenprostalene should be administered by subcutaneous injection. Luteolysis occurs in 3-5 days after treatment, an ovarian follicle develops to produce estrogen, the cervical canal relaxes and dilates, uterine contraction is enhanced and the purulent exudate in the uterus is expelled. Treatment procedures for endometritis should be followed as required if the purulent exudate is still present after treatment.

The judgement of recovery should be made in the same way as endometritis. The possibility of recovering and conception is greater if the diagnosis is made and treatment is given earlier. If the discovery and treatment of the disease is late, the endometrium is destroyed, the uterine walls become fibrous and a complete recovery and conception may be difficult to attain.

(7) Mucometra and hydrometra

A condition in which various amounts (30 milliliters to several liters) of fluid is retained in the uterus. These fluids include various types of liquid ranging from watery and viscous mucus to semifluid mucous masses containing denatured tissue fragments.

The disorder is considered to be unrelated to microbial infection. Histopathological findings show cystic degeneration of the endometrium and atrophy of the uterine walls although their causes are unknown. The disorder accompanies follicular cysts and occurs in individual animals with anomalies of the uterus, cervical canal and vagina and persistent, rigid and imperforate hymen.

Rectal palpation reveals that both of the uterine horns are enlarged and thick, uterine walls are thin and have fluctuation and liquid matter is present in the uterine cavity. A viscous property of the liquid indicates mucometra and a watery property hydrometra. In some nulliparous cows with persistent hymen, the vagina as well as uterus is expanded.

Ultrasonography reveals a near circular or irregular-shape echo-free mass (liquid matter) in the uterus that includes a low-level echo (mucus) or minute high-level echoes (cells, tissue fragments).

The disorder is accompanied by a retained corpus luteum in many cases and causes the host to remain in an anestrous state so care must be taken not to make a misdiagnosis by consisting with pregnancy or pyometra.

Persistent hymen must be removed, if present, for treatment. In case the corpus luteum is present in the ovary, either one of $PGF_{2\alpha}$ preparations, i.e. 12-15 mg of dinoprost or 20-33 mg of tromethamine dinoprost (15-25 mg as dinoprost), or one of $PGF_{2\alpha}$ analogues, i.e. 500 µg of cloprostenol or 5 mg of etiproston tromethamine, should be administered once by intramuscular injection. Alternatively, 1 mg of fenprostalene should be administered by subcutaneous injection. Follicular cysts must be treated if they are complicating the disorder.

The disorder is diagnosed as healed if the liquid matter retained in the uterus has disappeared within 40 days of treatment. In general, the disorder often recurs after apparently successful treatment and there are few cases in which treatment results in complete recovery and conception. In cases in which persistent hymen was removed for the treatment of the disorder, care must be taken because scars formed after treatment may lead to vaginal stenosis and resultant dystocia.

2.2.2 A case in which estrus and mating does not lead to conception due to the disorders of the vagina, cervical canal, uterus, oviduct and ovary

(1) Vaginitis

Inflammation of the vagina, this disorder results from infection by bacteria or vaginal irrigation with irritating disinfectant and high-temperature wash, associated with dystocia, vaginal prolapse, coitus and insemination. It also occurs as a result of retention of the placenta, endometritis and cervicitis in many cases. In the case of bacterial infection, major causal bacteria include indigenous bacteria in the vulva and vestibule of the vagina such as

Staphylococcus spp., *Streptococcus* spp., *E. coli* and *Actinomyces pyogenes*. Vaginitis inhibits conception if the disorder accompanies endometritis and cervicitis but it heals spontaneously if it is mild in severity and without complications.

In many of the cows with the disorder, pyoid or cloudy mucus discharges from the vulva irregularly and the vaginal mucous membrane is congested, swollen and has pyoid mucus on the vaginal walls. In the case of severe vaginitis, stimulation from a vaginal examination and so forth causes pain. In the case of complications by cervicitis and endometritis, discharge of pyoid exudate from the external uterine orifice and congestion of ectocervical mucous membranes are present.

For treatment, vaginal irrigation with less irritant physiological saline or a zwitterionic or cationic detergent should be performed and drugs such as sulfanilamides and antibiotics applied to or infused into the vagina. The disease requires some time to heal but the prognosis is generally good. Diseases that are secondary to endometritis and cervicitis can be healed by treating these diseases.

(2) Urovagina

A condition in which part or most part of the urine flows backward into the vaginal floor and is retained temporarily or persistently. The disorder occurs because the broad ligament of the uterus and supporting tissues near the vagina that support the uterus and vagina relax due to aging, weakness, malnutrition and perinatal injuries and the inner part of the vagina sinks due to a loss of strength. The disease is accompanied by impaired ovarian function such as follicular cysts and ovarian subfunction in most cases and occurs rarely in animals with a normal estrous cycle. Thus, its close relationship to the secretion of sex steroid hormones is suggested.

In cows with the disease, the vulva faces upward because the vagina sinks forward so the urine is retained in the inner part of the vagina submerging the exterior uterine orifice. The vaginal mucous membrane is reddened and emits a strong urinary odor and the cervical mucus is suspended from the vulva like a thread since it is mixed with urine and rendered watery Cervicitis or endometritis follows if the disease lasts long.

Treatment must be tailored for the individual causes of the disease because urine collects in the vaginal floor soon after it is removed. Thus, marasmus and malnutrition must be improved by supplementing with nutrients and providing sufficient exercise and care. Appropriate treatments must be given to cows with inflammation of the uterus, cervical canal and vagina. For cows with mild urovagina in which urine is retained in the vaginal floor temporarily, the urine should be removed and the vagina irrigated with physiological saline or 5% glucose solution before infusing semen into the inner part of the cervical canal or the internal uterine orifice area. Surgery has been tried to restore the vagina if the vagina sinks to a serious extent, however, the disease recurs in many cases.

There are chances of conception in mild cases or cases of temporary retention of urine. In cases in which the disease results from marasmus and malnutrition, the improvement of constitution is needed and takes a significantly long period. There are no chances of recovery in cases of a depressed back due to aging and emaciation.

(3) Cervicitis

Inflammation of the cervical canal. It often accompanies endometritis and results from bacterial infection at the time of abortion, dystocia and retained placenta. It also results from injuries, and especially sticking injuries, to the cervical walls due to inappropriate handling of equipment for insemination and the diagnosis / treatment of uterine diseases.

The ectocervical part is congested and swollen and the third plicae circularis of the cervical canal is congested and, because it is swollen, turned over, exposed outside the external uterine orifice showing complicated morphology with its mucous membrane turned red or dark purple. A pyoid exudate discharges from the external uterine orifice. In some cases of old cervicitis, the external uterine orifice is maintained wide open and allows access to the uterus even during the luteal phase. Care must be taken because cervicitis is present independently quite rarely and is complicated by endometritis and vaginitis in most cases.

For treatment, the ectocervical part must be washed with warm water containing less irritant disinfectant or physiological saline and povidone iodine solution or an antibacterial agent applied to or infused into the cervical canal. The disease may heal spontaneously after repeated estrous cycles so care should be taken to maintain normal ovarian function while at the same time treating complicating endometritis and vaginitis.

The disease is diagnosed as healed if the congestion of the ectocervical region disappears and normal cervical mucus is present. If the disease is accompanied by endometritis, however, diagnosis of it being successfully treated is also necessary. The prognosis is generally satisfactory.

(4) Endometritis

Endometritis refers to inflammation of the endometrium and is the most frequently occurring disease of all uterine diseases, being one of the major causes of conception failure. The disease inhibits sperm from ascending by reducing their motility inhibits the growth of embryos and, if implantation is attained, Cause early fetal death and abortion.

The disease is divided into either the infectious type that is caused by bacterial, viruses, fungi and protozoans or the noninfectious type. In most cases of the infectious type, causal bacteria are *Staphylococcus* spp., *Streptococcus* spp., *E. coli, Actinomyces pyogenes, Pseudomonas aeruginosa* and other noninfectious indigenous bacteria that are present in the vulva, vestibule of the vagina, cow's body and cow sheds. Mixed infection with two or more bacterial species often occurs. Infectious bacteria include *Campylobacter fetus* and *Bruce/la abortus.* Bacterial endometritis is mainly caused by spontaneous or artificial infection of the uterus with bacteria through the vagina that results from coitus, insemination, embryo transfer and examinations and equipment for the diagnosis and treatment of uterine diseases or from procedures for perinatal disorders such as dystocia and retained placenta. The mechanism of bacterial infection of the uterus is related to the nutritional and health conditions of cows and is closely related to sex steroidal hormones. Thus, estrogen acts by protecting the uterus against bacteria and progesterone acts by suppressing this protective action and making the environment suitable for bacterial growth. The uterus in the early luteal phase is known to be particularly susceptible to bacterial infection and endometritis. The causes of endometritis of the noninfectious type include artificial factors such as the infusion of an irritable chemical solution into the uterus and uterine irrigation with high- temperature physiological saline.

Endometritis is divided into the acute and chronic types according to clinical findings and the type that is associated with discharging of abnormal secretion is referred to as secretive endometritis and the type that is not latent endometritis. Secretive endometritis is further divided into catarrhal endometritis in which hyaline mucus or hyaline mucus containing grayish-white streaks discharges from the external uterine orifice and purulent endometritis associated with discharging of purulent mucus.

Diagnosis is based mainly on a vaginal examination and, as required, on diagnostic uterine irrigation and an endometrial biopsy.

As a basic treatment, the inside of the uterus is washed with sterilized physiological saline (40-42 °C, a total of 2-4 liters) to remove its content and an intrauterine infusion for endometritis is administered. In cases of mild endomeritis that are not associated with a large amount of abnormal secretion, omitting uterine irrigation from the treatment procedure mentioned will not reduce the efficacy. In the absence of high effectiveness, however, uterine irrigation must be performed instead of uselessly repeating medications. For intrauterine infusions, penicillin and iodine solution are highly effective. The quantity of infusion should be 30-50 ml, a sufficient amount to cover the entire surface of the endometrium. If antibacterial agents are used for treatment, the relevant standards for use must be followed considering the possibility of these agents remaining in the body and appearing in the milk. To promote the self-cleaning action of the uterus associated with the appearance of estrous, tromethamine dinoprost, a PGF2a preparation, at a dose of 15-25 mg as dinoprost was administered once intramuscularly in the luteal phase with satisfactory results. However, uterine irrigation and intrauterine administration should be performed as required. Ovarian diseases such as ovarian cysts must be treated if they are present.

The disease is diagnosed as healed if an examination performed in the estrous period or 7-14 days after treatment according to the diagnostic method mentioned above reveals a loss of abnormal findings. The prognosis is generally satisfactory, however it is poor in cases in which the disease persists and the uterus is extremely loosened and suspended and the uterine wall is extremely thinned or thickened.

(5) Myometritis and perimetritis

These refer to inflammation of the myometrium and perimetrium, respectively, and Myometritis is often accompanied by endometritis or perimetritis.

Some cases of these diseases result from severe endometritis, injuries of the uterus and cervical canal at the time of dystocia, injuries of the uterus at the time of the correction of presentation, embryotomy and cesarean section and rough excision of retained placenta Some cases result from injuries such as perforations in the uterus due to medical instruments at the time insemination, embryo transfer and the diagnosis and treatment of uterine diseases. Perimetritis sometimes results from peritonitis.

In the case of Myometritis, rectal palpation reveals thickening and induration of the entire or localized part of the uterine wall and, in some cases, abscesses. Abscesses range from 2 cm to the size of a childš head and some sink into the abdominal cavity because of their weight. In the case of perimetritis, on the other hand, connective tissue fibers grow on the surface of the perimetrium (serous membrane) in the form of strings in some cases, both the uterine horns adhere to each other in some cases and the uterine horn adheres to the oviduct, ovary, broad ligament of the uterus, peritoneum, bladder or rumen in some cases. In acute cases, the disease shows the same symptoms as peritonitis and an examination of the uterus by rectal palpation causes pain.

For treatment, the disease is treated according to the same method as endometritis in case the disease is secondary to endometritis and no abscess is present. In the case of early-stage Myometritis that was initially caused by perforations in the uterus, an antibacterial agent is infused into the uterus or injected focally. If any abscesses are present, however, the disease is unlikely to be healed.

The disease does not impede conception as long as adhesions and induration do not affect uterine function. However, if the adhesion is extensive and severe and an abscess persists after treatment, there is little chance of recovery and conception or, if conception is attained, abortion may occur.

(6) Salpingitis

Salpingitis refers to inflammation of the oviduct. The disease causes infertility because inflammatory changes occur in the oviduct, an exudate collects within the duct, mucous membranes are thickened, the duct is closed and the movement of sperm and the ovum and thus fertilization are inhibited.

If the cause of the disease is bacterial infection, it results from endometritis or pyometra and from the ascent of the causal bacteria of retained placenta or puerperal metritis. If the cause of the disease is artificial, it results from inflammation associated with a perforation in the uterus produced at the time of uterine irrigation, insemination or embryo transfer and from repeated manual rupture of cystic follicles at the time of rectal palpation, rough excision of the corpus luteum and violent palpation of the oviduct.

The diagnosis of the disease is based on the examination of the oviduct by rectal palpation and requires years of experience and careful observation. In cases of mild Salpingitis, differentiation from the normal oviduct is difficult. In acute cases, the swollen oviduct can be felt since an exudate is retained in the lumen. Inchronic cases, induration of the oviduct resulting from the growth of connective tissues is felt. If the atresia of the oviduct is suspected, tubal insufflation is performed. The percentage of antemortem detection of Salpingitis by clinical examinations is low. The disease is detected as a result of autopsies in most cases.

If the disease is mild, the treatment method for endometritis is followed. If the atretic oviduct occurs unilaterally, insemination after confirming the growth of an ovarian follicle in the ovary on the same side as the normal oviduct may lead to conception. If the atretic oviduct occurs bilaterally, embryo transfer may be considered after confirming the normal functions of the ovary and uterus since there is no chance of fertilization.

(7) Hydrosalpinx and pyosalpinx

Hydrosalpinx refers to a condition in which adhesion of the mucous membranes of oviduct and atresia of the lumen occur and a transparent and watery secretion is present in the atretic lumen. If the secretion is purulent, the condition is referred to as pyosalpinx.

Both diseases are secondary to Salpingitis in many cases. Hydrosalpinx is sometimes present in the cases of congenital anomalies of the reproductive organs due to a recessive gene.

The diagnosis of the disease is based on the examination of the oviduct by rectal palpation. With Hydrosalpinx, the oviduct enlarges to 1.2 cm or more in diameter. If there is a large amount of secretion, the oviduct wall is thinned and has fluctuation so that the condition is sometimes misdiagnosed as an ovarian cyst. With pyosalpinx, the fimbria of oviduct adheres to the ovary or tissues surrounding the ovary in many cases and the oviduct expands to the size of the little finger or larger due to retention of secretion. However, distinguishing between these diseases by rectal palpation is not possible. Ultrasonograms of the secretion in the oviduct may help differentiate these diseases. There is no cure for the diseases.

(8) Ovulation failure

Ovulation failure refers to an abnormality in the ovulation process and includes delayed ovulation and anovulation.

1) Delayed ovulation

A condition in which there is a long period between estrus onset and ovulation although ovarian follicles grow in the ovary, estrus emerges and ovulation eventually occurs.

2) Anovulation

A condition in which ovarian follicles undergo regression to atresia, atretic corpus luteum or cysts without ovulating although ovarian follicles grow and estrous signs appear. This disorder is directly caused by abnormal LH secretion from the anterior lobe of the hypophysis or the delay, lack or loss of LH surge, but may also be related to abnormal secretion of FSH and estradiol.

The diagnosis of ovulation failure involves repeating rectal palpation over the estrous period to confirm the presence/ absence of ovulation by major ovarian follicles in the ovary. The diagnosis of delayed ovulation is made if ovulation occurs 36 hours after estrus onset followed by luteinization since ovulation normally occurs 2 hours after estrus onset in cows. Because estrus is detected by using the swelling and congestion of the vulva and the discharge of mucus from it as indicators, insemination is often repeated from several days before estrus onset and a misdiagnosis of the disease is made. The diagnosis of anovulation is made if ovulation does not occur after the presence of estrous signs and follicular growth, as indicated by rectal palpation, and findings in an examination of the ovary performed 7-10 days after the loss of estrous signs reveal follicular atresia, regression or cysts and a lack of luteinization.

If growing ovarian follicles are present, treatment includes administering 100-200 µg of fertirelin acetate or 10-20 µg of buserelin, both GnRH analogues, once intramuscularly to stimulate the anterior lobe of the hypophysis to induce endogenous LH surge as a means of remedying abnormal LH secretion. In addition, to supply LH, an intramuscular or subcutaneous injection of 1,500-3,000 IU of hCG or an intravenous or intramuscular injection of 200-400 Rab. U of bovine APG or an intravenous injection of 20-40 A.U. of swine APFSH is administered once.

Insemination is performed 9-24 hours after administration of hormone preparations depending on the status of estrus before and after the hormone administration. If insemination results in a failure and estrus returns, the hormone preparations mentioned above are administered within a short period from estrus onset and insemination is repeated. Administration of the aforementioned hormone preparations before estrous onset results in ovulation 30-36 hours after the administration. Thus, occurrence of ovulation 2 days after administration indicates that the treatment was effective. If ovulation occurs within 24 hours of administration, the ovulation was triggered by an LR surge that was induced by endogenous GnRH and not by exogenous hormones. In the case of absence of ovulation after treatment, rectal palpation is performed 7-14 days after treatment to see if additional treatment is necessary because a shift to ovarian quiescence or ovarian cysts may have occurred.

(9) luteal hypoplasia

Luteal hypoplasia refers to a condition in which luteal tissues are formed insufficiently after ovulation. It is divided into Hypoplastic corpus luteum and cystic corpus luteum depending on the shape of the corpus luteum.

1) Hypoplastic corpus luteum

The diagnosis of the disease is made if the corpus luteum grows insufficiently after ovulation, secretes progesterone insufficiently and undergoes regression too early with the estrous cycle shortened to about 10 days. A corpus luteum like this is often formed after the first ovulation following birth or delivery and after treatment of cows with ovarian quiescence with hCG or GnRH analogues. After the treatment of follicular cysts or in the cases of urovagina and endometritis, an estrous cycle of about 10 days is sometimes repeated due to insufficient luteinization after ovulation.

Because of poor luteinization, possible causes include reduced ability of the anterior lobe of the hypophysis to secrete LR and a lack of LH receptors in the ovarian follicles that ovulated and the corpus luteum that was formed later. Because the disease occurs in cases of urovagina and mild endometritis, luteolytic factors that are produced during the recovery phase of transient inflammation associated with endometritis in the early luteal phase may be one of the causes.

For treatment, 1,500 3,000 IU of hCG is administered intramuscularly or subcutaneously or 100-200 µg of fertirelin acetate or 10 20 µg of buserelin, both GnRH analogues, is administered intramuscularly during the period from onset of the following estrous to ovulation. Administration of the aforementioned hormone preparations to cases with existing hypoplastic corpus luteum may not prolong the estrous cycle in many cases. If present, urovagina and endometritis must be treated concurrently. The disease is diagnosed as healed if a normal corpus luteum is formed after treatment.

2) Cystic corpus luteum

For several days in the early luteal phase, a cavity retaining fluid is often present in the central part of the bovine corpus luteum but the cavity gradually becomes occupied by luteal tissues as the corpus luteum grows until finally it is lost. Cystic corpus luteum refers to a condition in the functional luteal stage in which the cavity within the corpus luteum is so large that the surrounding luteal layer is thin, and the cavity retains fluid.

Diagnosis of the disease is made if by rectal palpation at 2-3 days after ovulation, i.e. in the early luteal phase, the corpus luteum is found to be larger than normal and a sense of strain or fluctuation is felt because of fluid retention and if these conditions persist until 7-14 days after ovulation. Palpation presents findings quite similar to those of ovarian cysts in many cases. Processus of the corpus luteum protruding from the ovarian surface like a mushroom are present (Photograph 2-4&5 (p.37)) because the disease develops after ovulation but rectal palpation may fail to detect them. The length of the estrous cycle is within the normal range. An ultrasonography examination of the corpus luteum reveals inside a circular or irregular-shaped echo-free image 1.0 cm or more in diameter. The thickness of the luteal layer ranges from extremely thin to thick depending on the case. The range of progesterone levels in blood varies from normal to low. Views differ as to whether fluid is retained in the luteal cavity because of decreased ability to form the corpus luteum due to abnormal function of the anterior lobe of the hypophysis to secrete LH or if luteinization is insufficient because of fluid retention after ovulation.

Treatment is unnecessary if the luteal layer of the cystic corpus luteum is thick because such corpus luteum retains normal function. If the cavity inside the corpus luteum is exceptionally large and the surrounding luteal layer extremely thin, a solid corpus luteum can be formed in 3-4 days by eliminating the fluid inside the luteal cavity by pressing with fingers from over the rectal wall or by aspirating it with an ovarian syringe. Eliminating the fluid inside the luteal cavity by the seventh day from insemination is effective in achieving conception if the fluid was formed after insemination. The disease is healed if a normal corpus luteum is formed after treatment.

(10) Ovaritis

Ovaritis refers to inflammation of the stroma of the ovary and adhesion of the ovary to the surrounding tissue often occurs. Although ovarian follicles grow and estrous occurs in the early stage of the disease, these ovarian follicles cannot achieve ovulation and undergo atresia and regression or, in some cases, degenerate to cysts. In the case of chronic Ovaritis, connective tissue grows on the stroma of the ovary and inhibits growth of ovarian follicles,

resulting in anestrus due to a loss of ovarian function. Abscesses are rarely formed. Artificial causes include violent palpation of the ovary in rectal palpation, rupture of ovarian cysts and cystic corpus luteum by pressing with fingers and removal of the Corpus luteum. The disease also results from bacterial endometritis and Salpingitis and from peritonitis associated with injuries due to metal foreign matter and tuberculosis.

Diagnosis in the early stage of the disease is relatively easy because rectal palpation reveals slightly to severely swollen ovaries and mild pain is present. In chronic cases, adhesion of the ovary to the surrounding tissue impedes palpation but diagnosis is possible because it is shrunk and inelastic.

No appropriate treatments are available. The disease may heal spontaneously if the degree of inflammation and adhesion to surrounding tissue is mild. The prognosis is poor if the disease occurs bilaterally and severely, but if the disease occurs unilaterally and estrus and growing ovarian follicles are present, insemination may lead to conception. If farmers choose conception, delivery and milking in spite of poor prognosis, embryo transfer may be tried after confirming the normal estrous cycle and ovarian function.

2.2.3 A condition in which no abnormality is present in the reproductive organs but no conception occurs even after three times of mating

(1) Repeat breeder

Repeat breeder refers to an infertile condition of unknown cause in which in spite of the normal estrous cycle and normal results of examinations of the ovary and accessory reproductive organs, no conception occurs after three times of mating at each estrous. The causes of the disease vary but fertilization failure and early embryonic death are considered to be the main causes. The causes of fertilization failure include congenital or acquired anomalies or infectious diseases of accessory reproductive organs such as the oviduct and uterus as well as reduced fertility of the Ovum and sperm due to poor properties of semen and untimely insemination. The causes of early embryonic death include mild bacterial infection of the uterus and abnormalities in the environment of the oviduct and uterus due to quantitative imbalance between estrogen and progesterone involved in movement, growth and implantation of the embryo. Involvement of chromosomal aberration is also probable.

Because of a lack of definitive diagnostic criteria, infertile cows are indiscriminately diagnosed as the disease in some cases. Examinations performed from different angles may reveal that some of these cases are caused by other disorders such as ovulation failure, atretic oviduct and latent endometritis.

Treatment includes improving the feeding environment and breeding management, which are thought to be predisposing factors. If early embryonic death is considered to be the cause, underlying factors are assumed and the following diagnostic treatment procedures are performed. If mild bacterial infection of the uterus is suspected, uterine irrigation is performed♂ and a drug containing an antibacterial agent is infused into the uterus in the luteal phase before insemination or within 1 2 days of insemination, according to the treatment method for endometritis. To promote luteinization, 1,500 3,000 IU of hCG is administered intramuscularly or subcutaneously or 100-200 μg of fertirelin acetate or 10-20 μg of buserelin, both GnRH analogues, is administered intramuscularly at the time of insemination or within 3-7 days of ovulation. If implantation failure of the embryo due to reduced luteal function is suspected, 200 500 mg of long-acting progesterone is administered intramuscularly 4-5 days and 10-12 days after insemination. Healing of the disease is diagnosed if conception occurs after the improvement of the feeding environment

and breeding management or treatment. If no conception occurs in spite of the treatments mentioned above, there is no chance of recovery.

2.2.4 Abnormalities during the pregnancy and perinatal periods

(1) Fetal death

1) Fetal mummification

A condition in which a fetus that died in the mid-pregnancy period, fetal fluid, fetal membrane and placenta shrink and harden and turn chocolate color because body fluids from them are absorbed aseptically and remain in the uterus for a long period. Causes of fetal death vary. Malnutrition, summer heat, infection with bovine viral diarrhea mucosal disease (BYD-MD) virus and *Neospora caninum,* torsion of umbilical cord and a recessive gene on the autosome are known to cause the disease. Estrus is absent because the production of luteolytic factors by the endometrium is suppressed and the corpus luteum is retained.

A vaginal examination reveals pregnancy findings, rectal palpation reveals a failure of growth of the fetus and uterus matching the fetal age, fetal fluid is quite little or lost and the uterus lacks fluctuation. The uterine wall is thin and rough, the placenta is not palpable and the fetus feels like a hard body. Vibrations characteristic to the mid-pregnancy period are not felt on the uterine artery and the persistent corpus luteum is present in the ovary. These conditions occur one or more months after fetal death when the fetus has undergone sufficient mummification. In practice, fetuses in various stages of mummification are found.

For treatment, either one of $PGF_{2\alpha}$ preparations, i.e. 12-15 mg of dinoprost or tromethamine dinoprost at a dose of 15-25 mg as dinoprost, or 500 µg of cloprostenol, a $PGF_{2\alpha}$ analogue, is administered once by intramuscular injection to facilitate regression of the retained corpus luteum and growth of ovarian follicles and promote contraction of the uterus and dilation of the cervical canal to expel the mummified fetus. PGF_{2a} is highly effective and promotes self-cleansing action of uterus, resulting in conception in many cases.

The mummified fetus is usually expelled in 2-4 days after injection. If the mummified fetus is retained in the vagina with a colicky symptom, the fetus is removed with a hand. If these procedures fail, a cesarean section is performed. The disease is diagnosed as healed if estrus occurs after the mummified fetus has been expelled.

2) Fetal maceration

Fetal maceration is one of the postmortem changes that occur when the fetus dies in the uterus but abortion does not occur and is characterized by a condition in which the fetus dissolves without the action of bacteria leaving in the uterus a thick, viscous cream-like fluid and the fetal skeleton. The cervical canal is closed during the early stage but relaxes gradually until bacteria enter the uterus and decompose the fetus. In many cases the cause of fetal death is unidentified.

Estrus is absent. By a vaginal examination, the exterior uterine orifice is slightly open and a dirty, bad smelling fluid discharges from it. In cases in which a long time has passed since fetal death, this fluid may contain fetal hair, hoof or bone fragments. Rectal palpation reveals the hard fetal skeleton in the lowered pregnant horn. The persistent corpus luteum is often present in the ovary. Normally, no apparent systemic symptom is present.

Treatments are the same as fetal mummification if the dead fetus is in the uterus and the corpus luteum is retained in the ovary. If the decomposition of soft tissue advances and bones are separated, administration of $PGF_{2\alpha}$ preparations will result in some of the bone fragments being retained in the uterus in many cases. If the macerated fetus is removed, treatment methods for endometritis are followed. However, removing all the bone fragments is difficult

whether they are removed through the cervical canal or through an incision in the abdominal wall. Although conception is possible if the macerated fetus is discovered in the early stage and eliminated, chronic endometritis persists due to remaining bone fragments. Prognosis is poor if the degree of uterine relaxation and thickening is significant.

(2) Abortion

Abortion refers to a condition in which the fetus is delivered live or dead before reaching the stage of viability and in which the delivered fetus is generally of a macroscopical size. A case in which a viable fetus is delivered before the completion of gestation period is referred to as premature birth and a case in which a nonviable fetus is delivered during this period or a fetus dies immediately before or during the delivery process as stillbirth.

Abortion is divided into infectious abortion that is caused by infection with pathogens such as bacteria, viruses, protozoans and fungi and noninfectious sporadic abortion depending on the cause. Infectious diseases of the reproductive organs that cause infectious still abortion in cows, pathogens, clinical conditions, diagnosis and countermeasures are summarized in Tables 2-2 (p.35) and 2-3 (p.35). Sporadic abortion is caused by falling of the fetus in the uterus, bruising in the abdomen, low nutrition and poisoning, serious systemic diseases, a shortage of progesterone secretion, increased secretion of adrenocortical hormones due to stress, inappropriate handling of the uterus during gestation period and genetic factors such as fetal chromosomal aberration.

Eliminating causes and predisposing factors is the basis of treatment. In the case of infectious abortion, hygienic management is important, and vaccination is employed. To prevent habitual abortion in which abortion occurs at the same stage each time in spite of a lack of infection or exogenous sensitization in particular, 50 200 mg of progesterone is administered several times intramuscularly at 2 to 3-day intervals starting from 2 to 3 weeks before the abortion-prone period or 300-600 mg of its depot preparation (long-acting preparation) is administered 3 or 4 times. Occurrence of abortion of 5% or higher is a serious matter requiring diversified examinations of causes for the establishment of a proper treatment method.

Table 2-2 Abortion in cows due to viruses and protozoans

(modified from Gibbons, 1972)

Name of diseases	Pathogen	Clinical conditions	Diagnosis	Countermeasures
Akabane disease	Akabane virus	Abortion, premature birth, stillbirth, malformation (hydranencephaly, articular curvature of calves)	Viral isolation Serologic reaction Fluorescent antibody technique	Vaccination
Chuzan disease	Chuzan virus	Abortion, premature birth, stillbirth, malformation (hydranencephaly, cerebellar hypoplasia of calves)	Viral isolation Serologic reaction Fluorescent antibody technique	Vaccination
Aino virus infection	Aino virus	Abortion, premature birth, stillbirth, malformation (cerebellar hypoplasia, articular curvature and wryneck of calves)	Viral isolation Serologic reaction Fluorescent antibody technique	Vaccination
Infectious bovine rhinotracheitis (IBR)	Bovine herpes-virus 1	Abortion, respiratory symptoms, pustular vulvovaginitis, balanoposthitis	Viral isolation Serologic reaction Fluorescent antibody technique ELISA	Vaccination Isolation Discontinuation of mating
Bovine viral diarrhea mucosal disease (BVD-MD)	BVD-MD virus	Enteritis, diarrhea (primary), abortion, mummification, malformation (cerebellar hypoplasia)	Viral isolation Serologic reaction	Vaccination Isolation
Rift valley fever	Rift valley fever virus	Abortion, hepatic necrosis	Viral isolation Serologic reaction	Eradication of external parasites Restriction of movement
Trichomoniasis	*Trichomon-as foetus*	Sterility, pyometra, abortion (1-4 months of pregnancy)	Detection of Trichomonas sp. by culture of preputial content	Insemination Treatment of infected cows
Neosporosis	*Neospora caninum*	Abortion, stillbirth, mummification, non-purulent encephalomyelitis, non-purulent myositis	Histopathological study Immunohistochemical examination of interstitial protozoans	Prevention of approach of dogs

Table 2-3 Abortion in cows due to infection with bacteria, Chlamydia spp. and fungi

(modified from Frank and O' Berry, 1966)

Name of diseases	Pathogen	Clinical conditions	Diagnosis	Countermeasures
Brucellosis	*Brucella abortus*	Abortion (6-9 months of pregnancy) Conception failure Orchitis, Epididymitis	Serological reaction Bacterial isolation Clinical conditions	Vaccination* Examination and slaughter Isolation, disinfection
Campylo-bacteriosis	*Campylobacter fetus*	Temporary sterility Abortion (4-7 months of pregnancy)	Agglutination test of vaginal mucus Bacterial isolation	Artificial insemination Treatment of infected cows
Leptospirosis	*Leptospira pomona* Others	Hemolytic anemia Abortion (late gestation period) Agalactia	Serological reaction Bacterial isolation	Vaccination* Treatment (antibiotics)
Listeriosis	*Listeria monocytogenes*	Encephalitis Abortion	Bacterial isolation Clinical condition Histopathological study	Isolation, disinfection
Chlamydiosis	*Chlamydia psittaci*	Abortion (late gestation period) Hepatic lesions of the fetus Orchitis, Seminal vesiculitis	Isolation of pathogen Serological reaction Fluorescent antibody technique	Isolation Elimination of stress (prevention)
Mycotic abortion	*Aspergillus fumigatus*	Abortion	Fungal isolation Lesions of aborted fetus and placenta	Avoid using moldy feed

Note * Not practiced in Japan.

(3) Prolonged gestation

Prolonged gestation refers to a condition in which the gestation period far exceeds the normal range without signs of delivery or the start of delivery. Gestation with a period of 300 days or longer is generally recognized as being the disease. The fetus is excessively large or malformed in most cases.

The cause of the disease on the part of the dam is thought to be the failure of a series of endocrine mechanisms. These mechanisms include increased secretion of fetal hypophysis-derived adrenocorticotropic hormone that triggers delivery, increased secretion of fetus-derived adrenocortical hormone, an increased estrogen level in the dam's blood, production of $PGF_{2\alpha}$ in the placenta, increased contraction of the uterus due to a drop-in progesterone secretion and an increase in oxytocin receptors in the uterus and the start of labor. Causes on the part of the fetus include a recessive gene on the autosome that is supposed to be a predisposing factor of the abnormality in the hormone secretion mechanism mentioned above. Manifestations of the disease occurring from this cause include a giant fetus, facial malformations, cerebral deficiency, hypophysis deficiency, severe adrenal hypoplasia or deficiency as well as stunting and malformation of the fetus. An example of nonhereditary congenital malformation is an outbreak of prolonged gestation associated with fetal malformation due to alkaloidal intoxication resulting from ingestion of Veratrum stamineum by pregnant cows.

Diagnosis is made if prepartum prodromal signs are absent when the due date of calving has passed, such as mammary tension, relaxation of the sacroiliac and sacrotuberous ligaments, shift to a depressed state, significant loosening of the vulva and discharge of cloudy, viscous mucus.

For treatment, either one of $PGF_{2\alpha}$ preparations, i.e. 12-15 mg of dinoprost or tromethamine dinoprost at a dose of 15 25 mg as dinoprost, or 500 µg of cloprostenol, a $PGF_{2\alpha}$ analogue, is administered once by intramuscular injection. Alternatively, 1 mg of fenprostalene is administered subcutaneously. If parturient signs do not appear within 72 hours of injection, injection is retried at the same dose as above or 10 20 mg of dexamethasone is administered once intramuscularly. In addition, 10-20 mg of estroil or 5- 8 mg of estradiol benzoate may be administered concurrently. If diagnosis was delayed and the fetus grew too large, delivery through the birth canal is significantly difficult in many cases if delivery is induced. In these cases, cesarean operation should be performed from the beginning. Dexamethasone is known to temporarily reduce immunocompetence of the body so the presence of infection should be confirmed beforehand and useless repeated administration avoided.

The disease is healed if the fetus has been delivered. In the case of induced delivery by means of medication, the fetus may die because labor pains are so mild that delivery takes a long time. Thus, continuous observation is necessary after a procedure to induce delivery has been performed. Care must be taken because fetal malformation, and especially malformation of the head, may lead to dystocia. Retained placenta occurs more frequently in the case of induced delivery than in spontaneous delivery.

(4) Uterine torsion

A condition in which the pregnant uterus is twisted around its long axis. Because the great curvature of the bovine uterine horn is not supported by the broad ligament of the uterus, a pregnant uterus that has sunk into the abdominal cavity in the form of a sac is easily moved by the action of the stomach and intestines. As the gestation period advances, factors such as the growth of the fetus, fetal membrane and placenta and an increase in fetal fluid cause imbalance in weight and size between the pregnant and non-pregnant horns. An increased estrogen

level in the late gestation period also relaxes supportive tissue such as the broad ligament of the uterus. In these circumstances, torsion of the pregnant uterus is likely to occur as a result of spontaneous straining associated with the lying and standing behavior of the dam, fetal movement and labor.

The disease that occurs in the mid-gestation period (6-7 months of gestation) occurs in the uterine body in front of the interior uterine orifice. Symptoms include sudden restless behavior, decreased appetite and tympanites. Rectal palpation reveals a strained uterus with reduced fluctuation, folds that show the direction of torsion and strained bilateral broad ligaments of uterus and uterine arteries. The disease that occurs during the period from the opening to expulsion periods is without uterine torsion because the fetus has moved to the uterine body and is likely to occur in the uterine cervix that has become elastic, relaxed and open. Labor pains persist for a long time but the fetal sac and fetus are not seen from the vulva. By palpation with a hand in the vagina, a number of spiral folds are felt formed on the vaginal wall running from the posterior to anterior portions. The direction of torsion is identified from the clear folds formed on the upper vaginal wall or from the fact that the pudendal lip on the opposite side of torsion (left pudendal lip in the case of right torsion) is swollen.

For treatment, the most appropriate method of reducing and delivering a fetus for the case in question must be determined by taking into account fetal size and the clinical conditions of the dam. If the torsion is slight (around 90°), the fetus is drawn according to the methods for dystocia. The fetal head (the hip in the case of posterior presentation) is guided from the uterine cervix to the vaginal birth canal. If the fetal hoof and head are palpable, repositioning is performed in a standing posture. If the uterine body is twisted, the uterine cervix is twisted without dilating sufficiently, the fetus is impalpable, the dam is unable to assume a standing posture due to weakness or reposition is unfeasible in a standing position, reposition is performed by letting the dam lie on the same side as torsion with the fore and hind legs bound separately and turning the cow quickly. If these methods are found to be ineffective, a cesarean section is performed. A cesarean section is applicable only when the uterus is not necrotized.

The prognosis of the dam and calf is satisfactory if the torsion was detected in the early stage and remedied but poor if the torsion was severe and lasted long.

(5) Dropsy of fetal membrane

This condition, in which a large amount of fetal fluid is retained in the fetal membrane cavity divides into hydramnios and Hydrallantois. These occur independently but are sometimes combined. Hydrallantois is thought to occur more frequently than hydramnios.

1) Hydramnios

This disease is associated with a genetically or congenitally abnormal fetus. Because the swallowing of amniotic fluid is impeded in an abnormal fetus, an increasing amount of amniotic fluid collects in the amniotic cavity resulting in an expanded amniotic cavity. Thus, expansion of the abdomen occurs in the late gestation period and gradually becomes noteworthy. Dystocia often occurs due to expansion of the uterus, uterine inertia and fetal malformation and the fetus is abnormal and dies without exception.

In mild cases, observation is continued while waiting for delivery. In severe cases, abortion is induced by administering $PGF_{2\alpha}$ or a $PGF_{2\alpha}$ Analogue or dexamethasone according to the treatment method for prolonged gestation. The prognosis of the reproductive ability of the dam is satisfactory.

2) Hydrallantois

This disease is usually associated with uterine diseases. The placenta is significantly swollen with edematous and necrotic changes. The cause of the disease is thought to be abnormalities in the allantoic chorion function including the permeability of vessels that exudate and absorb body fluids.

The disease may be unnoticeable until delivery if it is mild. In severe cases, symptoms suddenly appear during a period of 5-20 days after the mid-gestation period with significant expansion of the abdomen that may suggest twins or triplets. The darn shows reduced appetite, arrest of rumination, constipation as well as fibrillated pulsation and rapid breathing. Rectal palpation reveals an unusually expanded uterus but the fetus is impalpable. The abdomen continues to expand as the disease progresses and the dam will be weakened and eventually unable to stand. Dystocia is likely to occur due to malpresentation and uterine inertia and the fetus dies within the uterus or immediately after birth.

For treatment, abortion is induced immediately as in hydramnios. Severe cases may require cesarean section. Because of severe dehydration, the dam needs a large amount of transfusion. The prognosis of the reproductive ability of the dam is poor if it escapes death.

(6) Dystocia

Dystocia refers to a condition during the delivery process in which the first stage (opening period) or the second stage (expulsion period) is so prolonged that delivery is difficult or impossible without assistance.
Dystocia occurs from causes derived from the fetus more frequently than from those derived from the dam. Causes derived from the fetus include faulty fetal disposition, fetal gigantism and fetal malformation and those derived from the dam faulty uterine disposition and abnormalities in the birth canal and labor.

Diagnosis should include inquiring of farmers about the number of times of delivery, time that has passed since delivery, the presence/ absence of discharge of fetal fluid and actions that have been taken to relieve dystocia. If a long time has passed since delivery onset, the general condition of the dam should be examined carefully. Disinfected fingers are inserted slowly through the birth canal to check for injuries, the degree of dilation of the uterine cervix, status of the fetal sac and fetal presentation and position. To check whether the fetus is alive or not, palpation of the fetus is perfom led from over the fetal membrane if rupture of the bag has not yet occurred or directly if the rupture has occurred at the time of examination.

The procedure includes performing reposition and assisting in delivery if the cause is faulty fetal disposition. When infeasible and when the cause is fetal gigantism and malformation, cesarean section is performed. When the fetus is dead, the fetus is delivered by means of fetotomy.

If the cause is uterine hernia of the dam, the fetus is delivered quickly by cesarean section and so forth. If the cause is an abnormality in the birth canal, the procedure involves moistening the birth canal with mucilage using disinfected fingers, relaxing and dilating the insufficiently dilated portion by massage and trying to deliver gradually. When infeasible and when the cause is severe stricture and obstruction, the fetus is delivered by incision of the insufficiently dilated, constricted or obstructed part or by cesarean section. If the cause is uterine inertia, after confirming that the birth canal is secure, labor is promoted by administering oxytocic, or stimulating the dorsal part of the transitional zone between the vestibule of vagina and vagina, or administering 20-150 units of oxytocin, an uterotonic, intravenously, intramuscularly or subcutaneously or 1.7-12.0 mg/kg of spiriting sulfate subcutaneously or intramuscularly.

The prognosis is satisfactory if the fetus is delivered with assistance or by fetotomy without injuring the birth canal. Sequelae include puerperal metritis, puerperal fever and peritonitis and severe cases of these conditions result in poor prognosis. If the birth canal is severely injured and healed, stricture of the cervical canal and vagina may lead to recurrence of dystocia.

(7) Vaginal prolapse

This refers to a condition in which part or the entire vaginal wall protrudes from the vulva. It tends to occur during the mid- to late gestation period and sometimes after delivery. The possible mechanism is that increased abdominal pressure presses the uterus and vagina backward and high amounts of estrogen produced by the placenta relaxes the supportive tissue of the vagina and vulvar sphincter. If the birth canal and vulva is injured or relaxed due to dystocia, the disease is likely to occur frequently during the following gestation. A long period of raising on an inclined floor with the front part higher and the rear part lower is a major cause of the disease that occurs in the mid- to late gestation periods.

In infertile cows, the disease often occurs during the estrous phase but infrequently during the luteal phase. Involvement of estrogen in the pathogenicity of the disease is also suggested by the fact that it often accompanies follicular cysts.

During the last stage of pregnancy, a reddened vaginal membrane is often exposed from the vulva in a hemispherical form when in a prone position but is reduced in a standing position. In severe cases, the entire vaginal wall along with the ectocervical portion protrudes to produce a mass the size of a human head, which will not be reduced if in a standing position. As time advances after the prolapse, the vaginal membrane degenerates to necrosis in summer and dries to necrosis in winter due to insufficient blood supply, contamination with feces, mechanical stimulation and drying. In some cases, the back part of the prolapsed vaginal wall serves as a hernial sac, into which the bladder and fatty tissue enter. Cases in which the bladder enters the reversed vaginal sac are prone to dysuria.

In mild cases, the disease heals spontaneously after delivery with satisfactory prognosis but tends to recur in the following gestation. Treatment of severe cases of the disease involves disinfecting the vulva and surrounding parts with cationic or zwitterionic detergent, washing the prolapsed vagina with physiological saline or mildly irritating disinfectant and reducing in a low-front and high-back standing position. A vulvar truss is installed after reduction. In the case of poor results with straining induced, vulvar suture is performed, or opening of the pudendum is rejected by passing a tape underneath the skin surrounding the vulva and both ends are ligated, or abdominal fixation or these methods are combined. When present, follicular cysts are also treated. If the entire vaginal wall prolapses, spontaneous healing is unlikely and reduction may not improve conception failure.

(8) Uterine prolapse

Uterine prolapse refers to a postpartum condition in which part or the entire uterus is reversed and prolapses from the cervical canal to the outside of the vulva.

The disease is often caused by dystocia due to fetal gigantism, postpartum persistent labor pain, retained placenta and relaxation of the uterus and birth canal. Raising pregnant cows on a floor with a steep high-front and low-back slope is known to be a major predisposition to the disease.

In some cases, the uterus is reversed and prolapses outside the vulva in the form of a dark red sac, which

has a number of placentas lined in parallel on its surface. Part or most of these placentas have fetal placentas attached to them or all of them have lost fetal placentas. The prolapsed uterus is contaminated with blood and feces, has congestion and edemas due to a circulation failure, and these conditions worsen as time passes resulting in necrosis. The disease is sometimes associated with secondary laceration, perforations or partial defects of uterine tissue. Straining occurs repeatedly during the period shortly after prolapse but gradually weakens and disappears in the long run. Appetite decreases with the passage of time and pulse and respiration rates increase, causing dysstasia and, in some cases, collapse.

Farmers should be instructed to keep the prolapsed uterus clean while covering it with a moistened cloth or a plastic sheet to protect it from drying. Reduction should be started immediately if only a short time has passed since prolapse, the uterus has no or few injuries and the congestion and edema are mild. If a long time has passed and the uterus has injuries and advanced congestion and edema with clear systemic symptoms.

Reduction is performed carefully in combination with symptomatic treatments by use of cardiotonics and transfusion. When performing reduction, the cow is made to assume a low-front and high-back standing posture, when feasible, and in the case of strong straining, extradural anesthesia of the coccygeal vertebrae is performed beforehand.

Reduction involves irrigating the surface of the prolapsed uterus with moderately warm sterile physiological saline or a mildly irritating disinfectant followed by wiping. If the fetal membrane placenta is attached, it is detached with fingers but should not be detached forcibly. The prolapsed uterus is placed on a disinfected broad and strong rubber cloth, which is held by two assistants, and is held slightly higher than the vulva. The operator reduces the prolapsed uterus gradually from the cervical canal by taking advantage of the pauses of straining. Meanwhile, the uterus is sometimes irrigated with sterile saline or Ringer's solution to keep it clean and warm and prevent it from drying. After reduction, the uterus is redressed with fingers inserted deep inward. After redressment, I-2 g of Aureomycin is infused into the uterus to prevent infection of the uterus. In addition, 30-50 units of oxytocin is administered intravenously, subcutaneously or intramuscularly as an uterotonic. To prevent uterine prolapse from recurring, the cow with a vulvar truss installed is tethered on a floor with a low-front and high-back slope and, as required, vulvar sutur is performed. In creases in which the injuries and contamination of the prolapsed uterus are serious, an antibacterial agent is administered locally and systemically for 3-5 days and symptomatic t r e atments are continued because puerperal metritis is likely to follow.

If injuries of the prolapsed uterus are absent or mild and systemic symptoms are absent, the disease does not affect the following conception in many cases. However, because adhesion and induration may remain on the reproductive organs, farmers should be guided to receive examinations of the reproductive organs 20-30 days after delivery.

(9) Retained placenta

The placenta is usually expelled 3-8 hours after delivery of the fetus. In some cases, the placenta is not expelled within more than 12 hours of delivery of the fetus. This condition is referred to as retained placenta.

The causes of this condition are varied and have not yet been clarified. In some cases it occurs because detachment of the fetal placenta from maternal placenta is difficult because of placental inflammation, in some cases it occurs because the detached placenta is not expelled due to early contraction of the cervical canal and uterine inertia. Generally speaking, it preferentially occurs in cows with high milk yield, cows that are obese during the dry up period and cows that take insufficient exercise. It frequently occurs in cows that have undergone abortion, premature birth, stillbirth, dystocia, twin and triplet delivery and induced delivery. The disease is sometimes caused by lack of selenium and vitamin E.

Diagnosis includes confirming that part or the entire fetal placenta is retained in the uterus and part of the

fetal membrane is suspended from the vulva when 12 hours passed since delivery of the fetus. The detached placenta may be simply retained m the vaginal floor so the fetal membrane suspending from the vulva should be pulled lightly to determine whether the placenta is detached or not. General conditions should also be checked.

Although there is a controversy, no treatment procedures are performed for retained placenta, in principle, if there are no systemic symptoms such as fever and anorexia. If the retained placenta is left untreated while waiting for spontaneous extrusion and the fetal membrane suspended from the vulva is likely to cause odors and contamination of cowsheds, the fetal membrane is cut at the vulva while pulling the membrane lightlyy. Part of the placenta remaining in the uterus softens and Liquefies spontaneouslyas time passes, discharges as exudate-like lochia and is expelled within 7-10 days of delivery. If the placenta liquefies and remains in the uterus without being expelled, a $PGF_{2\alpha}$ preparation or a $PGF_{2\alpha}$ analogue is administered. An antibacterial agent for endometritis is infused into the uterus after expulsion. Systemic symptoms are present, an antibacterial agent is administered into the uterus systemically.

The conventional manual removal of the placenta is no longer employed because it causes injuries of the uterus, if however great care is taken, and bacteria that infect the injuries cause puerperal metritis and peritonitis associated with systemic symptoms. The method is also likely to cause persistent diffuse adhesion and induration of the reproductive apparatus resulting in reproductive inability. The method must not be used in the presence of systemic symptoms because the condition may worsen rapidly.

If the fetal placenta and lochia are removed without problems and the uterus recovers satisfactorily, the disease has no effects on the following conception. In the case of poor recovery, intrauterine administration or uterine irrigation is performed within one month of delivery according to the treatment method for endornetritis. If the disease is accompanied or followed by puerperal wound infection, various diseases occur one after another resulting in poor prognosis.

(10) Puerperal metritis

Puerperal metritis refers to inflammation of the myornetriurn or perirnetriurn. Myometritis is often accompanied by endornetritis or perirnetritis. It is caused by bacterial infection of the injuries of the uterine wall due to rough procedures for repositioning of the fetus, cesarean section and fetotomy at the time of dystocia and for retained placenta. Perirnetritis also follows peritonitis. The disease that occurs from delivery to the puerperal period shows a serious infectious systemic symptom with the inflammation spreading from the endornetriurn to perirnetrium and to the surrounding region. Causal bacteria include *Staphylococcus* spp., *Streptococcus* spp., *E. coli, Actinomyces pyogenes and Clostridium* spp.

The disease is characterized by bad smelling reddish-brown discharge from the uterus and is identifiable mainly by rectal palpation. In the case of rnyometritis, thickening, induration and, in some cases, abscesses of the entire or localized part of the uterine wall are palpable. Abscesses reach from 2 cm to the size of a childs head in diameter and may sink into the abdominal cavity because of their weight. In the case of perimetritis, fibrous connective tissue grows on the perimetrium in the form of strings in milder cases. In severer cases, both the uterine horns adhere to each other and the uterine horns adhere to the oviduct, ovaries, broad ligament of the uterus, peritoneum, bladder or rumen. In addition to rectal palpation, hematology to identify the characteristics of the disease and bacteriological examination. Of the discharge at the external uterine orifice are performed as appropriate.

In cases in which systemic symptoms such as fever and anorexia are present, systemic and local administration of antibacterial agents is performed to the full. Where a large amount of lochia is retained in the uterus and systemic symptoms will not disappear, a $PGF_{2\alpha}$ preparation or a $PGF_{2\alpha}$ analogue id administrated to expel the retained matter. If the treatment fails, a soft rubber is used to siphon the retained matter.

In case in which abscesses are absent and adhesion and induration are of a severity that does not affect the uterine function, the disease will not impede conception. If adhesion is extensive and strong and abscesses remain after treatment, the disease result in sterility.

Photograph 2-1 - 2-6 Ovary that shows an ovarian cyst and similar forms

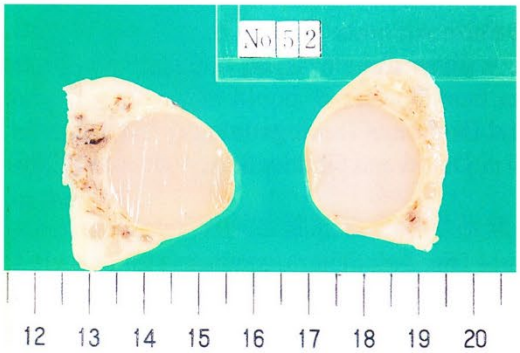

Photograph 2-1 Follicular cyst (FC)

A cystic follicle is present in each ovary.

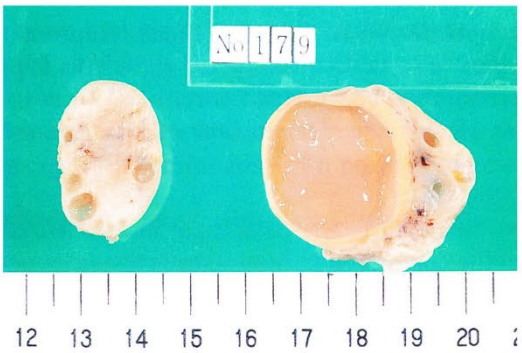

Photograph 2-2 Luteal cyst (LC)

Atretic corpus luteum derived from a cystic follicle is present in the right ovary.

Photograph 2-3 Luteal cyst (LC)

Part of the cystic wall that luteinized is present in the lower part of the right ovary and a cystic follicle undergoing regression to atresia is present in the upper part.

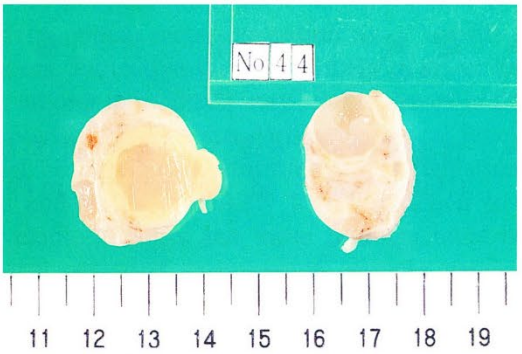

Photograph 2-4
Cystic corpus luteum (CCL)

Corpus luteum with a thin luteal layer that has processus and retains fluid at the center is seen in the left ovary and an ovarian follicle is seen in the right ovary.

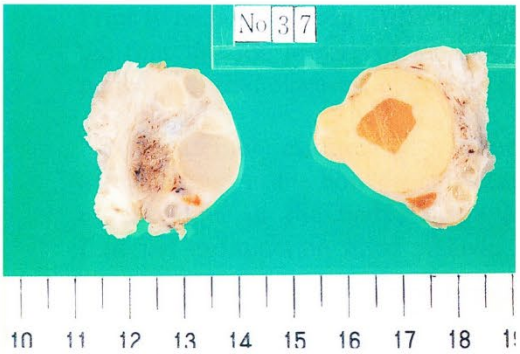

Photograph 2-5
Cystic corpus luteum (CCL)

Corpus luteum with a thick luteal layer that has processus and retains fluid at the center is seen in the right ovary and an ovarian follicle is seen in the left ovary.

Photograph 2-6 Coexistence of a gigantic ovarian follicle and corpus luteum (FCL)

A gigantic ovarian follicle undergoing regression to atresia and normal corpus luteum with processus are seen in the left ovary.

Chapter 3 Diagnostic method for reproductive disorder

Diagnostic methods for reproductive disorders in cows include external examination, vaginal examination, rectal palpation, ultrasonic examination as well as the determination of steroidal hormone levels in blood, bacteriological examination of the uterine content and endometrial biopsies. Of these, external examination, vaginal examination and rectal palpation are the most frequently used techniques when performing clinical examinations of a number of cows in the field. This chapter describes rectal palpation, which is the most commonly used a clinical setting.

3.1 Rectal palpation

Rectal palpation is the most widely used in making diagnoses of reproductive disorder in cows and pregnancy diagnosis. It is basic technique that will remain a main reproductive examination if a simple method of determining blood steroidal hormone levels in field and ultrasonic examination are introduced. However, since rectal palpation is a sensitive examination that relies on the sensation of the fingers, subjective views are likely to affect the result and difference in experience and sensation among individuals may lead to errors in the results. To eliminate this problem as much as possible to standardize technical levels and improve accuracy, the following points must be noted in performing rectal palpation.

First, the finding of the uterus, cervix, vagina and vulva are likely to be regarded low compared to a finding of a ovary showing dynamic changes, but these findings must be examined comprehensively. Thus, in this chapter, external examination, simple vaginal examination and internal examination are included in rectal palpation. Next, findings should be recorded in a unified format so that they can be shared among technicians.

3.1.1 Methods of rectal palpation

Prior to rectal palpation, sufficient information is obtained from farmers, including reproduction history of the sick cow, dates of conditions of delivery, history of perinatal period diseases, observations of estrus and insemination and treatment history.

Next, external examination is performed to check nutritional condition (BCS), hair, abnormalities in the hooves and feces as well as the presence/absence of spilled mucus on the floor or the body, shape of the labium and condition of labium mucosa.

External examination must precede internal examination because findings external examination change to some degree after internal examination.

When inserting a hand, the arm must be kept in parallel to the rectum to avoid generating a sense of incongruity. The feces are removed from the rectum. Simply pulling the rectal wall will not be sufficient to relax the rectal wall so the rectal wall must be pushed with the hand inserted to the inner part of the rectum. This operation is repeated several times to relax the rectal wall sufficiently. The rod-shaped uterine cervix under the rectum is held and drawn near. With the hand moved forward, the uterine horns are held between the thumb and middle finger at the point where the horns separate, the forefinger is placed under the ventral ligamentum interconuale (photograph 3-1 (p. 43)) and the entire uterus is lifted into pelvic cavity (Photograph 3-2 (p. 43)) so that the uterus is turned over. The forefinger must be placed under the ventral and not dorsal ligamentum interconuale because the dorsal ligamentum interconuale is so thin that it might be torn (Photograph 3-3 (p. 43)). This method allows detailed palpation of the uterine horns and oviduct because only the hand is left in the rectum at the time of palpation so that rectal tenesmus is reduced. If holding the uterine horn between the thumb and middle finger is not possible, the hand is placed under the uterine horn on the same side as the hand, the hand is lightly held to lift, and turned over so that the end of the horn comes to the fore. The opposite horn, which is slightly lifted at this time point, is

lifted similarly and turned over. The uterus is lifted onto the pelvis and turned over. Detailed palpation is also possible with this method. Inability to lift the uterus by these methods indicates the possibility of adhesion of the uterus and broad ligament of the uterus.

Palpation of the uterus involves applying light pressure to the horn while holding it between the thumb and other fingers and sliding the thumb across the horn. Palpation is performed on both horns to see if there is any difference. The ovaries are also lifted into the pelvic cavity along with the uterus. Palpation of the ovaries is performed by holding and fixing the proper ligament of the ovary between the middle and ring fingers (Photograph 3-4) and pressing lightly with the thumb, forefinger and middle finger. The intensity of the pressure should be such that when a spoon held with the thumb and forefinger is shaken lightly it does not move. By doing this, the depth in the ovary (size) and hardness (softness, hardness) of the corpus luteum of fluctuation of ovarian follicles are palpable. If the pressure is too low distinguishing the corpus luteum from ovarian follicles may be difficult resulting in a misdiagnosis. However, the pressure should not be so high as to eliminate to corpus luteum or rupture the ovarian follicle.

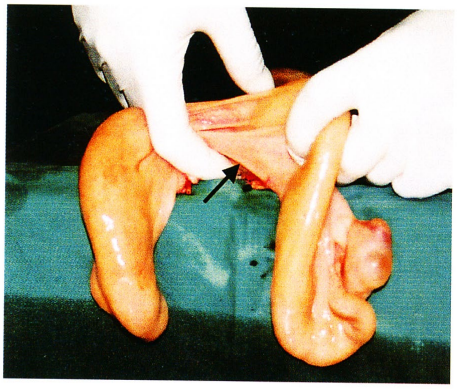	
Photograph 3-1 Method of lifting the uterus The forefinger is placed under the ventral Ligamentum interconuale, which is at the point where the horns separate, and the entire uterus is lifted to this side. The arrow indicates the ventral ligamentum interconuale.	Photograph 3-2 Palpation of uterus The lifted uterus is held with the thumb and other finger as if to enclose it and is palpated.
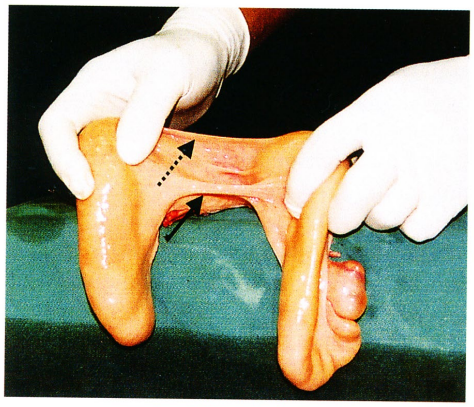	
Photograph 3-3 Points to note when lifting the uterus	Photograph 3-4 Palpation of the ovary

Ligamentum interconuale are divided into dorsal and ventral ligamentum interconuale. The dorsal ligamentum interconuale is thin and weak so it may rupture if the uterus is lifted by this portion. Thus, the finger must be placed under the ventral ligamentum interconuale. The arrow indicates the ventral ligamentum interconuale and the dotted arrow the dorsal ligamentum interconuale.	The proper ligament of the ovary is held with the middle and ring fingers and palpated with the thumb, forefinger and middle finger.

3.1.2 Recording rectal palpation findings

(1) Properties of spilled mucus

An observation is made to see if mucus or blood is attached to the pubic hair, tail, hind legs or floor. The property spilled mucus is classed as 3 class of 1) watery, 2) sticky or 3) starchy. Spilled mucus in each class is examined for color degree of 1) transparency, 2) opacity and the presence/absence of purulent or bloody matter. Blood or pus may be present instead mucus. If purulent matter is present, vaginoscopy is performed with a vaginal speculum to examine If vaginitis, cervicitis or endometritis is present.

(2) Shapes of labium

The shape of labium is classified into four grades as shown in Figure 3-1. The shapes of labium is affected by estrogen (E_2) and progesterone (P_4) labium swell and relax, if estrogen is dominant, and tight, if progesterone is dominant. Thus labium is ①Loose and ②swollen during the estrous phase and is loose in the case of follicular cysts. It is ③contracted and ④tight during the luteal phase.

（Note） Zebu cattle and Buffalo are not as described this way. Therfore, this shape of labium is a reference degree.

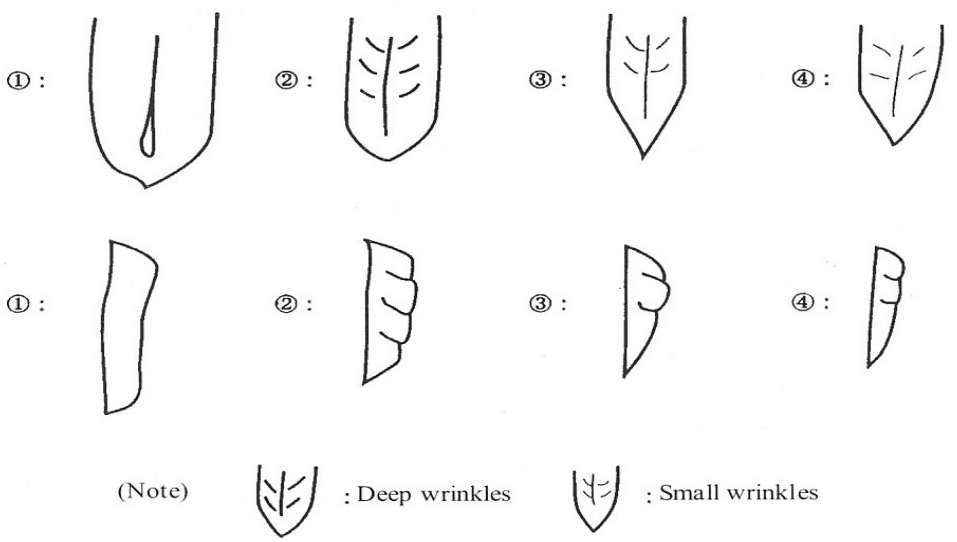

Figure 3-1 shape of labium

(3) Finding the labium mucous membrane

The labium is opened slightly with fingers and the labium mucous membrane is observed to see whether there is congestion or not and whether the mucosal surface is wet or dry. The labium mucous membrane is congested and moist when E_2 is dominant and is free from congestion and dry when P_4 dominant. Examination by a vaginoscope should be

performed as required because mucus, blood or pus can be detected in cows without sign of spilled mucus if the labium is opened.

(4) Finding in the Vagina

In normal condition the vaginal mucous membrane shows findings similar to those of the labium. If the vaginal mucous membrane has inflammation, however, it reddens and swells more than the labium and occasionally has abscesses. In general vaginitis, numerous millet-like tubercles 1-3 mm in diameter are present on the vaginal mucous membrane. Morphological abnormalities such as stricture and trabeculation are rarely present in the vagina. Vaginal examination may reveal a double external os of the cervix.

(5) Finding in the uterine cervix

The diameter of the cervix is measured at the point indicated by △ in Figure. The size is generally 3-4 cm (intermediate) and may be expressed as larger (large) or smaller (small). The large size is often observed in the case of delayed uterine involution or cervicitis and the small size in the case of contraction due to hormonal abnormalities. The diametral size of the cervix is expressed in terms of finger width as compared to the forefinger. It can also be expressed in terms of centimeters.

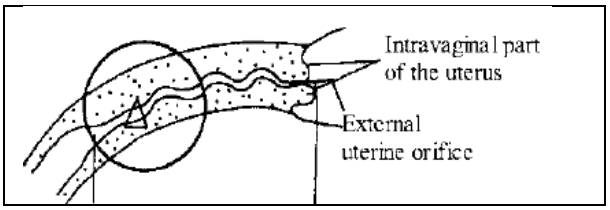

Figure 3-2 Location of the uterine cervix for palpation

(6) Finding the uterus

The uterine horns are examined at the part between * and ▲ as shown in Figure 3-3 for the size, shape, contraction and elasticity, thickness and internal condition and finding in the examination are recorded. Both of the right and left horns are examined. The size of the uterus is recorded in terms of finger width, by comparing with the forefinger, or to the nearest x cm. The uterus during the estrous phase is generally swollen and is 1.0-1.5 finger width in normal nulliparous cows and 1.5-2.5 finger widths in multiparous cows. The size during the luteal phase smaller than that during the estrous phase and is around 1.0 finger width and 1.5-2.0 finger widths, respectively. The uterine horns involute until both of them are the same size within 30-40 days of delivery. In some cows with dystocia, retention of fetal membrane and postpartum disease, however, the involution process tends to be slow and the right and left horns have different sizes

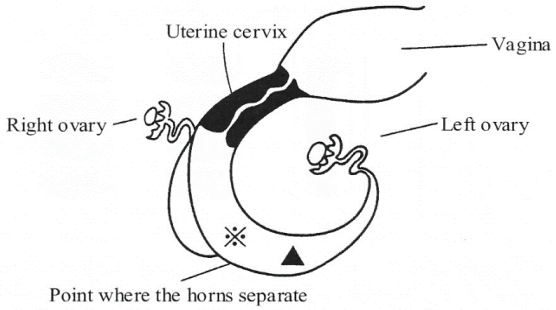

Figure 3-3 Location of the uterus for palpation: the part between * to ▲ of the uterine horn is examined.

(7) The shape of the uterus

The shape of the uterus is recorded according to the sectional shape of the uterine horns as shown in Figure 3-4. During the estrous phase, when the uterine cavity expands and the endometrium thickens, the shape is round or semiround in heifer and semiround in multiparous cows. During the luteal phase, the shape is semiround in heifer and semiround or oval in multiparous cows. A flat status is abnormal and is present in the case of ovarian quiescence and prolonged follicular cyst.

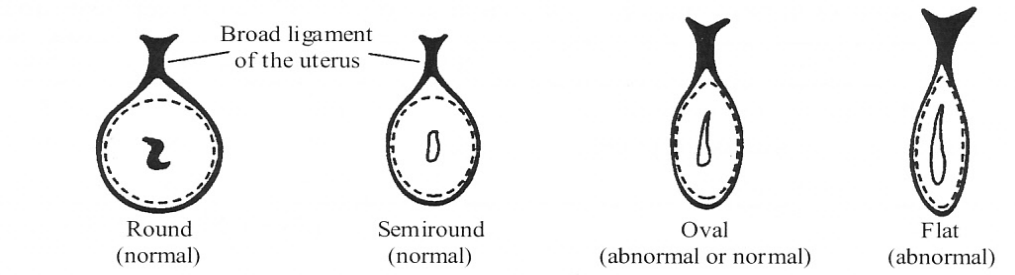

Figure 3-4 Shape of Uterus: A flat shape at any time indicates an abnormal finding.

(8) The contraction and elasticity

The contraction and elasticity of the uterus is particularly strong during the estrous phase when secretion of estradiol (E_2) increases and secretion of P_4 decreases.

+++: Rectal Palpation directly causes strong and continuous contraction of the uterus which feel like a round sausage.
++: Rectal Palpation causes contraction but strong contraction does not continue.
+: Rectal Palpation causes mild contraction and can identify the outline of the uterus.
± : Stimulation as strong as that caused by palpation does not induce contraction. Strong massage causes contraction of the uterus but it loosens as soon as stimulation is removed.
- : Strong massage does not cause contraction.

The rating for normal cows during proestrus if from +++ and the contraction will gradually become intermittent during postestrus. The rating is normally +during the luteal phase. Contraction finding and elasticity finding are almost the same.

(9) The thickness

The thickness of the uterus represents the thickness of the uterine wall (the thickness from the perimetrium to endometrium) and is recorded according to Figure 3-5. The rating of ++ is normal during the estrous phase and the rating of + during the luteal phase. The rating of ++ during the luteal phase suggests acute uteritis or luteal hypo function. The rating of - is abnormal whether during the estrous or luteal phase.

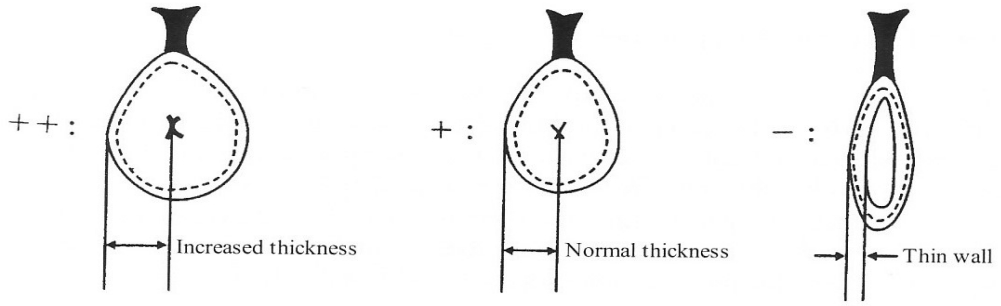

Figure 3-5 Thickness of the uterus

++; the uterus look like an edema and thickens and swells during the estrous phase when progesterone levels decrease and estrogen levels increase.

+; a normal state of the luteal phase of a cow receiving a sufficient effect of progestogen.

-; A condition during estrous and luteal phases in which the uterus is weak and thin is abnormal. This condition occurs in the cases of prolonged endomeritis and follicular cysts. However, care must be taken because the pregnant horn 30-45 days after insemination is also thin.

(10) The internal condition

The internal condition of the uterus are recorded according to figure 3-6. Internal condition include fluctuating of sticky retained fluids (mucus, pus, etc), a dead fetus, fetal membrane and fetal fluid. The rating of normal cows during the proestrus is + due to the retention of watery secretion but the rating is - is during other periods.

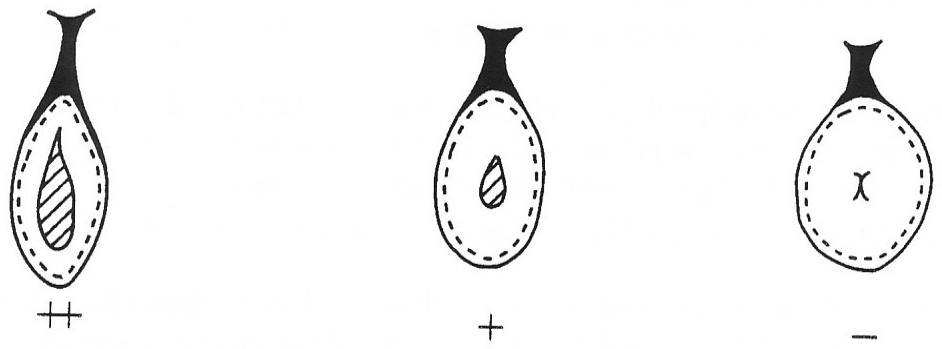

Figure 3-6 Internal condition of the uterus:

Note: The part from * to ▲ of Figure 3-4 (P.48) is examined. Otherwise the retained matter is not palpate.

(11) Finding the ovaries

The ovaries are examined mainly for major follicles, the corpus luteum, indurated parts and other important findings and the results are visualized by means of, for instance, illustration. The illustration does not need to be realistic but may be simplified as long as it is understandable.

As a general rule, the shape of the ovary expressed as a section plane on the long axis of the ovary by placing ovaries such that either the mesovarium edge is at bottom and the proper ligament of ovary is inside or the mesovarium edge is vertical and the both proper ligament of ovary is at the bottom. Finding in the examination of follicles, the corpus luteum and the indurated parts of ovaries induration are recorded according to Figure 3-7.

< Ovary in the estrous phase>	
①  ②  ③ 	1) Part of the estrous follicle protrudes from the ovary. 2) Regressed corpus luteum is painted black all over. The process must be indicate as well. 3) Confirm the ovulation are by pressing on it lightly with the finger tips and mark it with a wedge mark. Make sure to confirm the regressed corpus luteum in painted black all over to be recorded.
<Ovary in the luteal phase> Corpus luteum on days 3-5	
①  ②  ③ 	1) Confirm the new corpus luteum by pressing on it tightly with the fingers. Enter two oblique lines in the corpus luteum of this stage. Make sure that the regressed corpus luteum is painted black all over to be recorded. 2) If the presence of fluid in the luteal cavity is confirmed, the corpus luteum is illustrated as shown in 2). A broken corpus luteum is illustrated as shown in 3).

<Ovary in the luteal phase> Corpus luteum and follicles on days 6-15	
①  ②  ③  ④  ⑤ 	1) The corpus luteum is examined by pressure palpation for fragility, hardness and the presence/ absence of internal fluid. A fragile corpus luteum is marked with a few oblique lines and a solid corpus luteum is marked with oblique lines that increases as the solidity increases. If the corpus luteum is broke, a line is entered that shows the breakage. 2) If the presence of fluid in the luteal cavity confirm (Cystic corpus luteum), the severity is illustrated as shown in 2. 3) If the process of a corpus luteum that is palpable on days 12-15 is coated with the epithelium superficial, draw the outline of the ovary up to the as shown in 4). The shape of the process is drawn as accurately as possible. 5) Enter oblique line more densely in a hard corpus luteum. If follicles coexistent with the corpus luteum are palpated, determine the size, Phase and number of the follicles and whether they are dominant or subdominant follicles, and illustrate them inside the outline of the ovary as shown in 1) - 5).
<Ovary in luteal phase> Corpus luteum on days 16-19	
①  ② 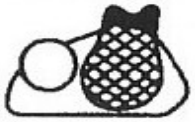 ③ 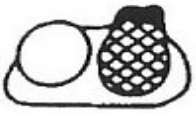	1) The sign of luteolysis is identified by palpating the process of the corpus luteum. The process with palpable hardness is painted black all over. 2) The inside of a corpus luteum that feels hard all over because of advanced regression is drawn with oblique crosslines. 3) A suspected next-time estrous follicle is illustrated as shown in 3). The inside of the regressed and hard corpus luteum is densely drawn with oblique crosslines.

<Other Ovaries>	
① 	1) Follicles other than estrous follicles are drawn inside the outline of the ovary as shown in 1) and 2) if they look protruding.
② 	
③ 	3) Abnormal follicles such as follicular cysts are drawn inside the outline of the ovary.
④ 	4) The outline of a follicle with a thick membrane is drawn thick.
⑤ 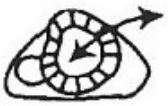	5) If a luteal cyst is suspected and confirmed by removal of the internal fluid and perforation, mark it with an arrow. It must be distinguished from a cystic corpus luteum with a process.
⑥ 	6) The indurated part is painted black all over.
⑦ 	7) An ovary with no clearly palpable follicles or corpus luteum is illustrated as shown in 7).
⑧ 	8) Palpable abnormalities on or near the oviduct are illustrated as shown in 8).
[Symbols]	
① 	1) A follicle was ruptured by finger during palpation.
② 	2) Internal fluid was removed by perforation.
③ 	3) The corpus luteum fell or dropped during palpation.
④ 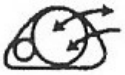	4) Internal fluid was removed by perforation and aspiration and a drug was injected into the follicular cavity.
⑤ 	5) Insemination (mating)
⑥ 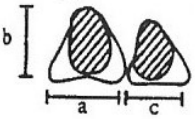	6) The size of the ovary: Expressed as a (long axis) x b (height) x c (thickness) and recorded to the nearest x mm by comparing with the thumb.

Figure 3-7 Recording ovarian findings

(12) Record Sheet for rectal Palpation

The record sheet we use in the rectal palpation is like the one in Figure 3-7. All information from farmers and finding in the ovaries must be entered. The sheet is devised to avoid entering omissions by adopting a system in which the appropriate answer is circled for items from the properties of spilled fluid to uterine finding. By analyzing rectal palpation

finding comprehensively, estimating time in the estrous cycle is possible. Thus the expected date of the next estrus can be indicated. By trying to follow this process, more sophisticated rectal palpation will be possible.

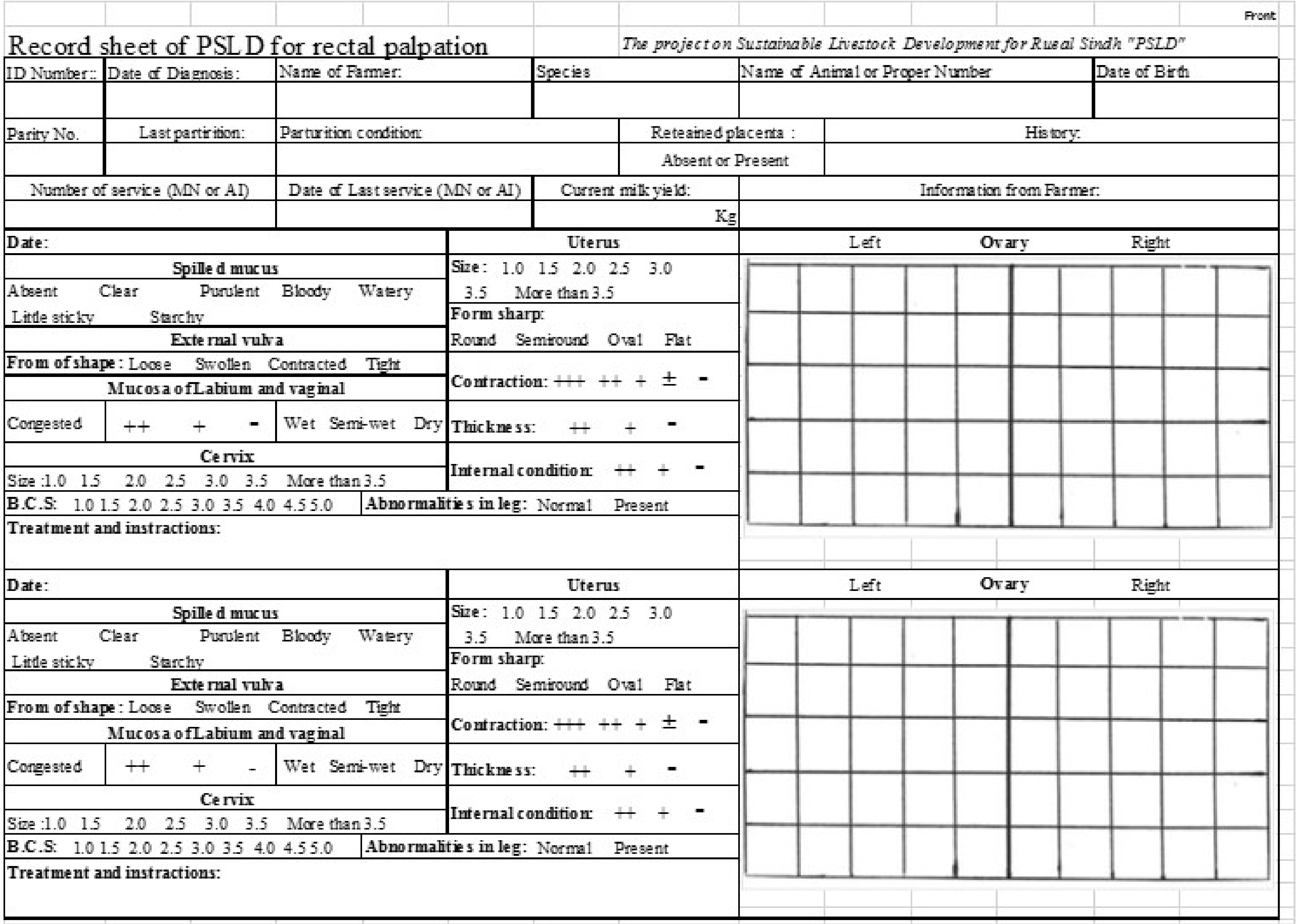

Front

Record sheet of PSLD for rectal palpation

The project on Sustainable Livestock Development for Rueal Sindh "PSLD"

ID Number::	Date of Diagnosis:	Name of Farmer:	Species	Name of Animal or Proper Number	Date of Birth

Parity No.	Last partirition:	Parturition condition:	Reteained placenta : Absent or Present	History:

Number of service (MN or AI)	Date of Last service (MN or AI)	Current milk yield:	Information from Farmer:
		Kg	

Date:

Spilled mucus

Absent Clear Purulent Bloody Watery

Little sticky Starchy

External vulva

From of shape: Loose Swollen Contracted Tight

Mucosa of Labium and vaginal

Congested ++ + - Wet Semi-wet Dry

Cervix

Size :1.0 1.5 2.0 2.5 3.0 3.5 More than 3.5

B.C.S: 1.0 1.5 2.0 2.5 3.0 3.5 4.0 4.5 5.0

Uterus

Size: 1.0 1.5 2.0 2.5 3.0 3.5 More than 3.5

Form sharp: Round Semiround Oval Flat

Contraction: +++ ++ + ± -

Thickness: ++ + -

Internal condition: ++ + -

Abnormalities in leg: Normal Present

Treatment and instractions:

Left Ovary Right

Date:

Spilled mucus

Absent Clear Purulent Bloody Watery

Little sticky Starchy

External vulva

From of shape: Loose Swollen Contracted Tight

Mucosa of Labium and vaginal

Congested ++ + - Wet Semi-wet Dry

Cervix

Size :1.0 1.5 2.0 2.5 3.0 3.5 More than 3.5

B.C.S: 1.0 1.5 2.0 2.5 3.0 3.5 4.0 4.5 5.0

Uterus

Size: 1.0 1.5 2.0 2.5 3.0 3.5 More than 3.5

Form sharp: Round Semiround Oval Flat

Contraction: +++ ++ + ± -

Thickness: ++ + -

Internal condition: ++ + -

Abnormalities in leg: Normal Present

Treatment and instractions:

Left Ovary Right

Figure 3-8 Record Sheet for rectal Palpation (Front)

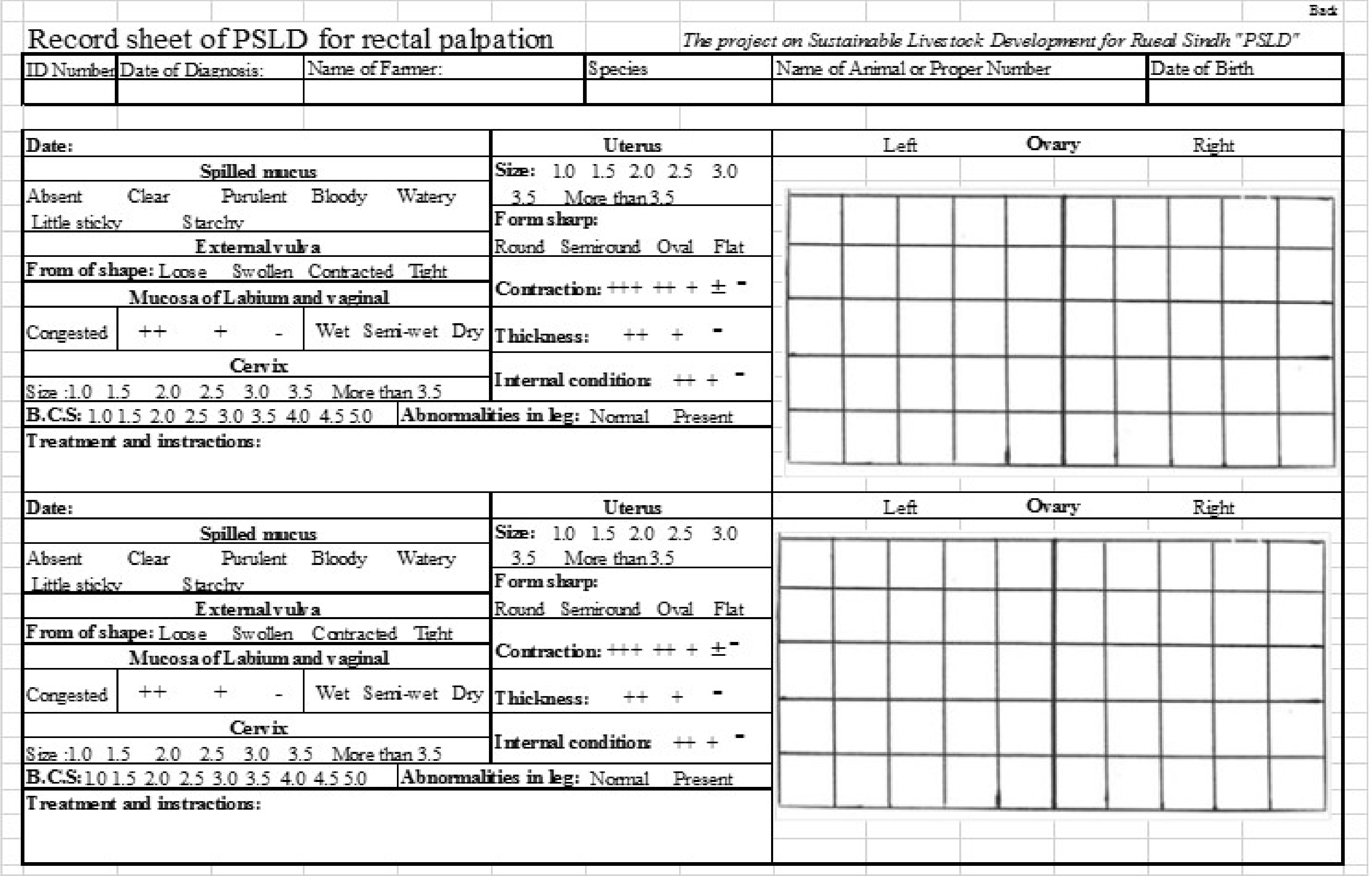

Back

Record sheet of PSLD for rectal palpation

The project on Sustainable Livestock Development for Rueal Sindh "PSLD"

ID Number	Date of Diagnosis:	Name of Farmer:	Species	Name of Animal or Proper Number	Date of Birth

Date:

Spilled mucus

Absent Clear Purulent Bloody Watery
Little sticky Starchy

External vulva

From of shape: Loose Swollen Contracted Tight

Mucosa of Labium and vaginal

Congested ++ + - Wet Semi-wet Dry

Cervix

Size :1.0 1.5 2.0 2.5 3.0 3.5 More than 3.5

B.C.S: 1.0 1.5 2.0 2.5 3.0 3.5 4.0 4.5 5.0

Abnormalities in leg: Normal Present

Treatment and instractions:

Uterus

Size: 1.0 1.5 2.0 2.5 3.0
3.5 More than 3.5

Form sharp:
Round Semiround Oval Flat

Contraction: +++ ++ + ± -

Thickness: ++ + -

Internal condition: ++ + -

Left **Ovary** Right

Date:

Spilled mucus

Absent Clear Purulent Bloody Watery
Little sticky Starchy

External vulva

From of shape: Loose Swollen Contracted Tight

Mucosa of Labium and vaginal

Congested ++ + - Wet Semi-wet Dry

Cervix

Size :1.0 1.5 2.0 2.5 3.0 3.5 More than 3.5

B.C.S: 1.0 1.5 2.0 2.5 3.0 3.5 4.0 4.5 5.0

Abnormalities in leg: Normal Present

Treatment and instractions:

Uterus

Size: 1.0 1.5 2.0 2.5 3.0
3.5 More than 3.5

Form sharp:
Round Semiround Oval Flat

Contraction: +++ ++ + ± -

Thickness: ++ + -

Internal condition: ++ + -

Left **Ovary** Right

Figure 3-9 Record Sheet for rectal Palpation (Back)

3.1.3 Basic diagram of estrus cycle

Diagram below shows estrus cycle of an ovary. Practice on drawing estrous condition properly like in this diagram.

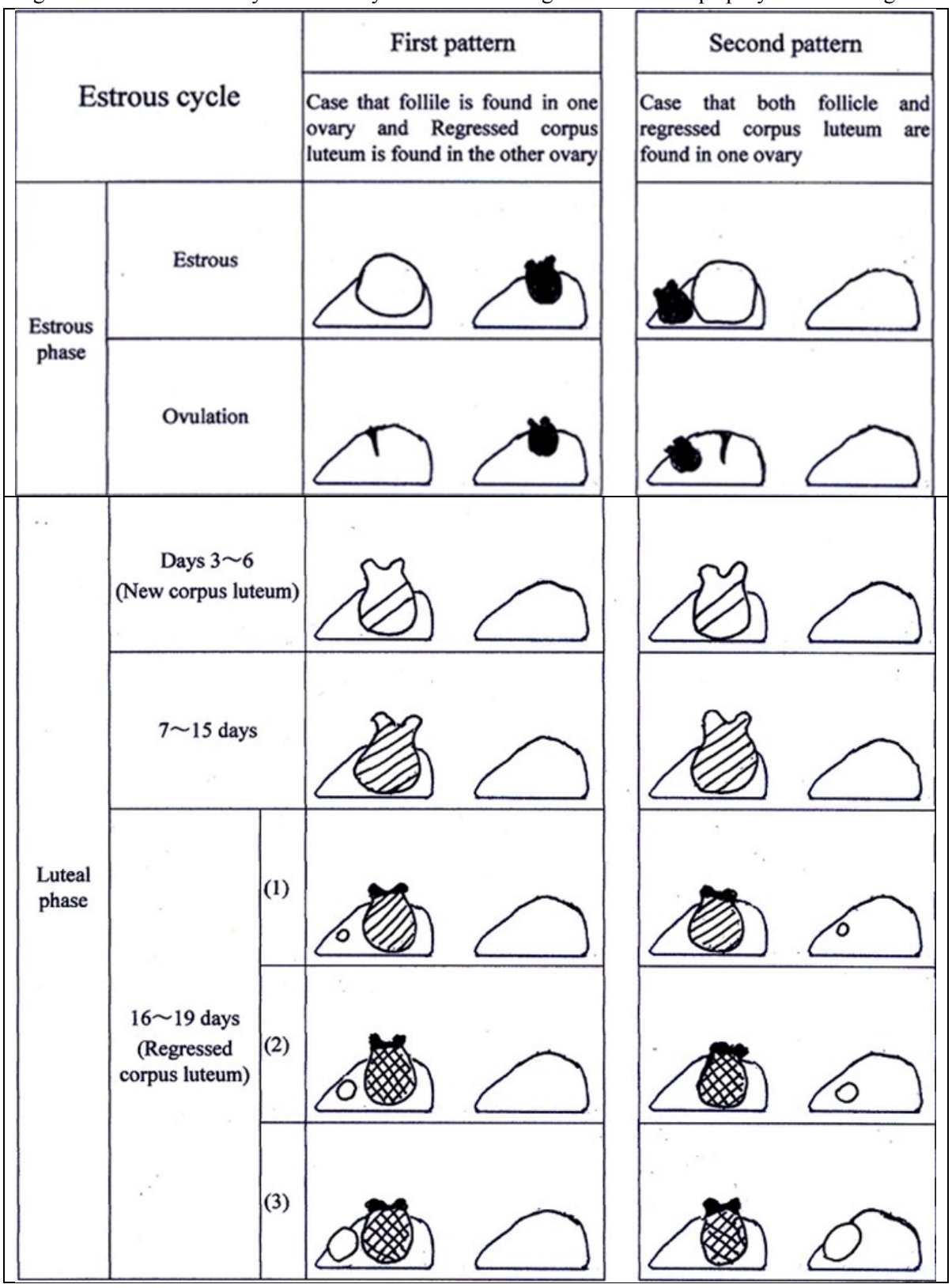

Figure 3-10 Basic diagram of estrus cycle Source Tominaga (2018)

3.1.4 Pregnancy diagnosis by rectal palpation

Pregnancy diagnosis is the most important technique of reproductive examination and require the most careful attention of technician. Early and accurate pregnancy diagnosis provides an effective means of performing breeding management for farmers.

A cow undergoing conception show the process as indicated in Table 3-1 and diagnosis of pregnancy by rectal palpation is possible from 30 days after insemination. Diagnosis is quite easy from 35 days after insemination if the uterus is turned over and the uterine horn can be palpated up to its end.

The pregnant horn swells and the uterine wall at the swelling point thin in the days from 30 days after insemination. Fluctuation due to fetal fluid, the fetal membrane and the vasa that develop into the fetal membrane can be palpated at the swelling point.

Pregnancy diagnosis involves holding the swelling part of the horn with the thumb and forefinger, applying low pressure two or three times to examine whether fluctuation is present, closing the finger lightly and sliding them across the horn and confirming the fetal membrane and thread-like vasa that develop into the fetal membrane.

The size of the pregnant horn in 2.0-2.5 finger widths 30 days after insemination, 2.5-3.0 finger width 35 days and 3.5 finger widths 40 days after insemination. The non- Pregnant horn also swells around 40 days after insemination. The labium and cervical canal contract and soft and large corpus luteum is present in the ovary on the same side as pregnant horn.

Table 3-1 Change in the findings in the ovaries, uterus and so forth from insemination to the 35th day of pregnancy

		Estrus (insemination)	After 10 days	After 18 days	After 21 days	After 26 days	After 35 days
Ovary							
Uterus	Size	1.5 to 2.0	1.0 to 2.0	1.0 to 2.0	1.0 to 2.0	Pregnant horn 1.5 to 2.0	Pregnant horn 2.0
	Shape	Round	Round to semiround	Round to semiround	Round to semiround	Round to semiround	Semiround
	Contraction and Elasticity	++ to +++	+	+	+	+	+
	Thickness	++ to +++	+	+	+	+	+
	Internal condition	+	-	-	-	Fetal fluid + (fluctuation)	Fetal fluid ++ Vasa +
Cervical canal		Open	Contracted	Contracted	Contracted	Contracted	Contracted
Vaginal mucosa		Wet	Dry	Dry	Dry	Dry	Dry
Labium		Swollen	Contracted	Contracted	Contracted	Contracted	Contracted

If rectal palpation 30-40 days after insemination reveals that the corpus luteum is present in both of the ovaries, both the uterine horns swell to the same extent and the fetal membrane and vasa that develop into the fetal membrane are palpable, twin pregnancy indicated.

If swelling of the uterus is 2-3 days delayed or the corpus luteum is small and hard or the labium cervix are loosened, an hCG or P_4 preparation should be administrated and reexamination performed because embryonic death or abortion is likely. The disease likely to be mistaken for pregnancy finding include pyometra and mucometra. Differential diagnosis for distinguishing these disease is shown in Table 3-2.

Table 3-2 Difference in uterine finding from rectal palpation among the cases of pregnancy, pyometra and mucometra

	Pregnancy	Pyometra	Mucometra
Size of the horn	Asymmetric except in the case of twin pregnancy	Symmetric in many cases	Symmetric or asymmetric
Contraction	Observable until the 3rd month of pregnancy	Weak	Absent
Thickness	Present in location, other than swollen part, which is thinned.	Present of absent	Absent
Endometrium	Flat. Rough at 70 days of gestation onwards because of growth of caruncles	Coarse textured	Flat
Fetal membrane and vasa that develop into feta membrane	At 30 days of gestation onwards	Absent	Absent
Medium uterine artery	Develops on the pregnant horn side and shows clear pulsation at 3 month of gestation onwards	Does not develop and is of the same size on both sides	Does not develop and is of the same size on both sides

An accurate diagnosis is made 30-45 days after insemination by the presence of the fetal membrane and vasa that develop into the fetal membrane. All technicians must master this skills.

3.2. Ultrasonic Examination

Like rectal palpation, ultrasonic examination is advantageous in that it can be performed on the same subject without invading living tissues. Unlike rectal palpation findings, the images generated are objective, which is the greatest advantage of ultrasonic examination. The method is especially useful when the ovaries and uterus cannot be examined by rectal palpation because of obesity. However, the difference in the hardness of the corpus luteum in the ovary and elasticity of the uterus, which can be felt by rectal palpation, are difficult to evaluate by this method. It also takes longer to obtain images for use in diagnosis than for rectal palpation so examining a number of subjects on the same occasion is difficult.

3.2.1. Advantage and Disadvantage of the Ultrasonic Examination

The advantages and disadvantages mentioned fallow must be considered when performing ultrasonic examination as used in reproduction examination.

(1) Advantage

1) Like rectal palpation, ultrasonic examination is advantageous in that it can be performed on the same subject without invading living tissues. It is also many times repeatedly.
2) Unlike rectal palpation findings, the images generated are objective, which is the greatest advantage of ultrasonic examination.
3) The method is especially useful when the ovaries and uterus cannot be examined by rectal palpation because of obesity.

(2) Disadvantage

1) The difference in the hardness of the corpus luteum in the ovary and elasticity of the uterus, which can be felt by rectal palpation, are difficult to evaluate by this method.
2) It also takes longer to obtain images for use in diagnosis than for rectal palpation.
3) The examining a number of animals on the same occasion is difficult.

3.2.2 Ultrasonograph

Mobility is an important factor in performing ultrasonic examination of cows in the clinical setting. The equipment must be compact so a portable type of ultrasonograph is often used. A knapsack type of ultrasonograph has been developed recently and its mobility is improved.

Many types of probes are available varying depending on the frequency, scanning system and shape. Ultrasonic examination as used in reproduction examination is performed via the rectum so a small-size probe of the linear or convex type with a frequency of 5 MHz or 7.5 MHz is suitable.

	FHK company Model HS-101V for cattle Probe: Small linear type
Photograph 3-5Knapsack type of Ultrasonograph	

3.2.3 Examination methods

1) A cow to be examined is retained in some facility.
2) The tail fixed to the body.
3) The feces in the rectum are removed.
4) The rectal wall is sufficiently relaxed.
5) A probe is inserted into the rectum and pressed on the rectal wall to visualize the cervix, uterus and ovaries.
6) The reproductive organs are kept as is during examination.
7) (When the cross section of the uterine horn is examined, however, the uterus is turned over as in rectal palpation to obtain satisfactory images.)
8) When visualizing the ovaries, rectal palpation is performed before hand to obtain ovarian findings. Based on these findings, the probe is operated along the long axis of the ovary such that the image of the corpus luteum and follicles are maximized.

3.2.4. Findings in ultrasonic examination

- Reading ultrasonographic images requires skills like other diagnostic imaging methods.
- One must be familiar with the images of normal reproductive organs before attempting to examine whether there are abnormalities in images.

(1) Findings in the normal estrous cycle

1) Uterine cervix

The vertical section image of the cervix is rectangular and the plicae circular is echogenic (photograph 3-6 and 3-7). The lower part of the cervix is sometimes undulated during the luteal phase. This indicates a condition in which the cervix is contracted by the effect of P_4. The cervix is thicker during the estrous phase compared to the luteal phase and the lower part appears linear. An echo-free line resulting from retention of mucus is present in the cervix of the estrous phase. The circular muscle layer appears as slightly echogenic circle in a cross sectional image of the cervix (on the right of photograph 3-6 and 3-7). The echo free central part of the cervical canal is often visualized during the estrous phase.

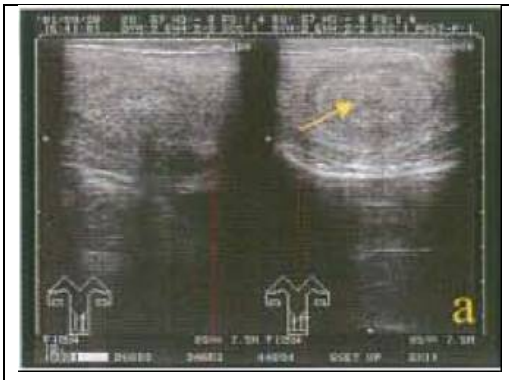

Photograph 3-6 Cervix of estrous phase

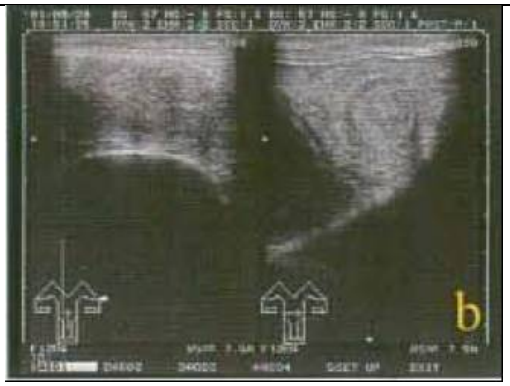

Photograph 3-7 Cervix of luteal phase

[The cervix is thicker and the circular muscle layer is larger during the estrous phase (a) than the luteal phase (b)]

2) Uterus

Because the uterine body is short, ultrasonic examination of the uterus focuses on the uterine horns. Vertical sectional imaging of the horn shows a long-curved image. However, the shape varies depending on the location of the uterus so comparing images directly is difficult. On the other hand, cross sectional imaging shows a round or elliptic image with a slightly echogenic elliptical layer (circular muscle layer) at the center of the uterine wall (photograph 3-8 and 3-9). Thus comparing individual images is easier with cross section than vertical sections. During the estrous phase, the uterine cavity often, appears as an echo-free expanded body due to the retention of watery secretion.

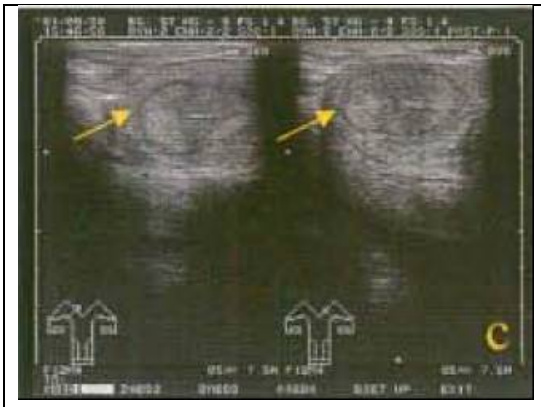

Photograph 3-8 Uterine horn of estrous phase

Photograph 3-9 Uterine horn of luteal phase

[The cross section of the uterine horn reveals an expanded circular muscle layer in the estrous phase (c) compared to the luteal phase (d) as in the cervix.]

3) Ovary

a. Ultrasonic images of the ovary distinguish follicles, corpus luteum and stroma of ovary.
b. Follicle appear as echo-free circular images because of the presence of follicular fluid.
c. Those immediately prior to ovulation may appear as elliptic images.
d. Follicles 2-3 mm in diameter or longer can be identified although it depends on the equipment (frequency of the probe) used.
e. The corpus luteum appears as a slightly echogenic homogeneous image. Cystic corpus luteum is often viewed even during the normal estrous cycle. An ultrasonic image shows an echo-free portion within slightly echogenic corpus luteum.
f. The stroma of the ovary is more echogenic than the corpus luteum. Its out line may not be well defined because of the surrounding tissues (photograph 3-10 and 3-11).

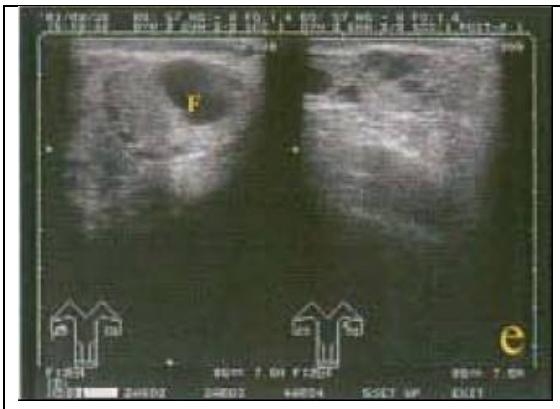

Photograph 3-10 Ovaries of estrous phase

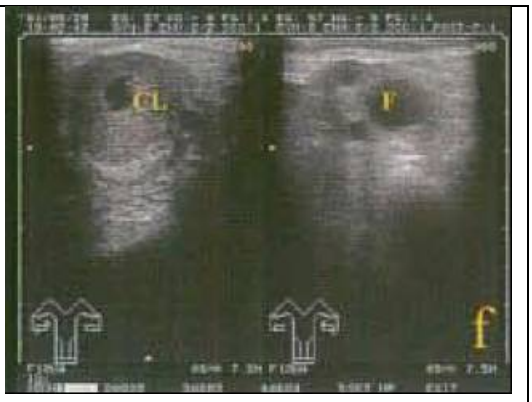

Photograph 3-11 Overies of luteal phase

[This indicates thickening of the endometrium. Within the ovaries (e and f) the follicle (f) is echo-free and the corpus luteum (CL) is slightly echogenic. A small amount of echo-free fluid is retained in the cavity of CL in the right picture.]

(2) Abnormal findings

1) Uterine cervix

a. Ultrasonography rarely reveals malformation in the cervix but usually discloses, if any, acquired cervical cysts secondary to injuries and tears.
b. This refers to a retention cyst of the cervical mucosa and appears as an echo-free circle 1-5 cm in diameter. Cervical abscesses resulting from injuries and tears are echogenic.
c. Thus, ultrasonography distinguishes between cysts and abscesses of the cervix.

2) Uterus

Abnormalities in the uterus can be identified by ultrasonography only when there is abnormal retained matter in the uterine cavity such as when pyometra or mucometra is present. With pyometra, the uterine cavity is dilated and heterogeneously echogenic. The uterine wall either is or is not thickened. The endometrial surface may be irregular and ill defined. With mucometra, the uterine cavity is dilated as in pyometra but is echo-free. The uterine wall is thin and the endometrial surface is well defined (fallow photograph)

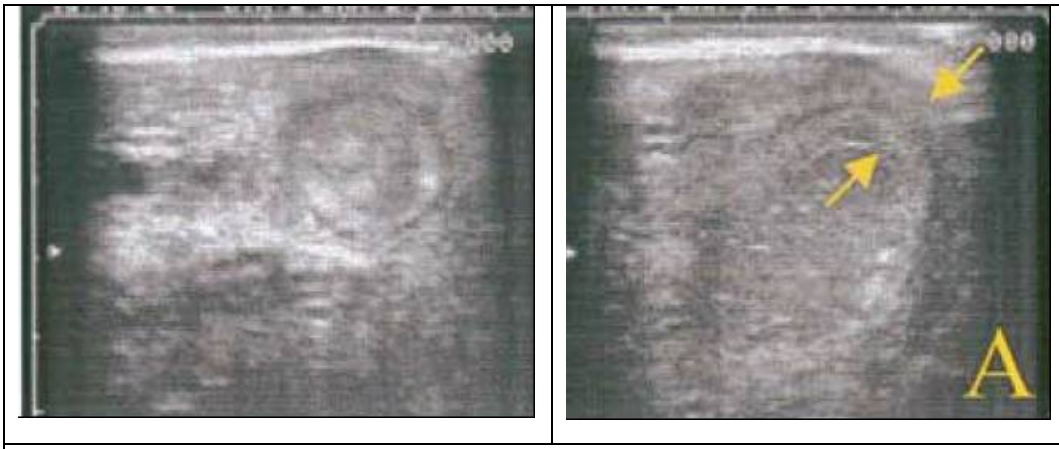

Photograph 3-12 Left and right of pyometra

[In the case of pyometra, the uterine lumen is echogenic and its boundary is ill defined. The uterine wall is not thinned in this case.]

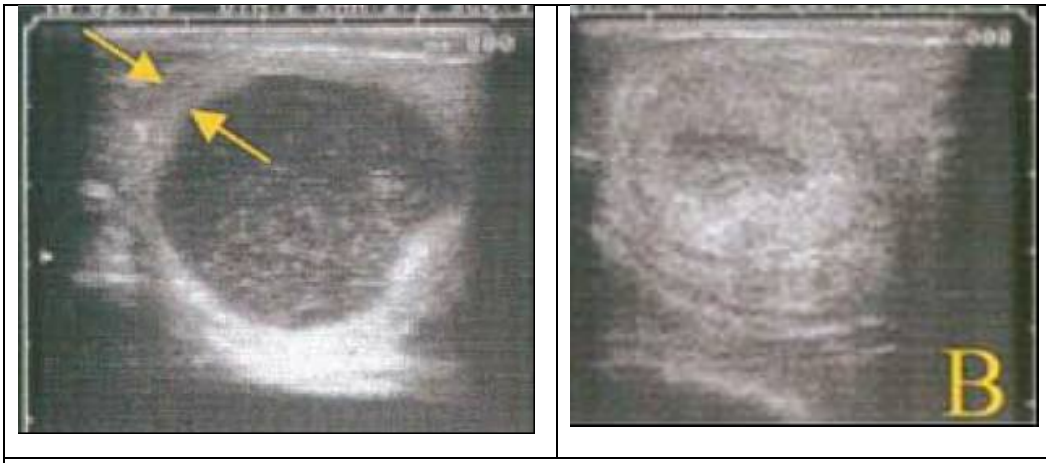

Photograph 3-13 Left and right of mucometra

[In the case of mucometra, the uterine lumen is mostly echo-free and minute echogenic particules are suspended in it. The uterine wall is thinned. In any case, care must be taken not to confuse it with pregnancy. The space between the arrows indicates the thickness of the uterine wall.]

3). Ovary

Follicular cysts are most easily identified by ultrasonography. Ovarian cysts are classified into follicular cyst and luteal cysts. Distinguishing a luteal cyst from a cystic corpus luteum is difficult but distinguishing a follicular cyst is possible with ultrasonography.

A follicular cyst appears as an echo-free circle within an echogenic theca folliculi with multiple follicular cysts, central part is deformed as seen in photograph 3-14. Follicles are separated by echogenic septa. In contrast, the surrounding part of a luteal cyst and cystic corpus luteum appears as a slightly echogenic layer because of the presence of a layer of luteal cells. The inside is echo-free because of the retention of fluid (photograph 3-15). A luteal cyst is circular like a follicle because of the lack of ovulation but a cystic corpus luteum is often elliptic or vasc-shaped because of ovulation.

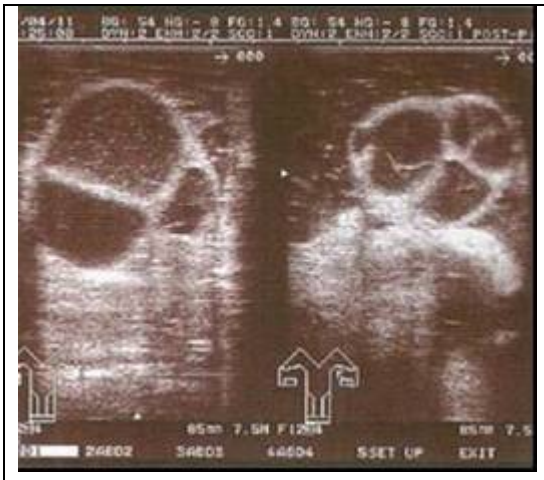	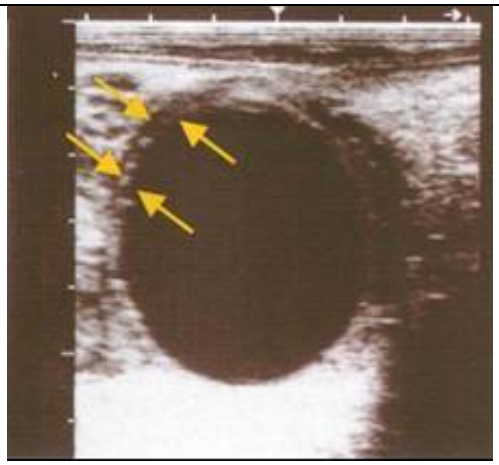
Photograph 3-14 Follicular cyst (7.5 MHz) Multiple follicles are present in the right and left ovaries. The theca follicle and the septum between follicles id echogenic. As seen in the picture, follicles appear as a semiround or sectorial shape if the ovary consists of many structure.	Photograph 3-15 Luteal cyst (5 MHz) The cavity is large and echo-free, similar to a follicular cyst. It is surrounded by a slightly echogenic luteal zone, which distinguishes it from a follicular cyst.

(3) Pregnancy Diagnosis by ultrasonic imaging

Many researchers reported that, in pregnant cows, vertical section of the uterine horn obtained by ultrasonography revealed echo-free thread-like images within the cavity of the pregnant horn from 15 days after insemination and these images increased to 2-3 mm by 20 days after insemination (photograph 3-16) and continued to grow until an embryo was seen. They also indicated however, that diagnosing pregnancy from these echo-free images in the uterine cavity 25 days after insemination or earlier is difficult because of the difficulty in distinguishing watery secretion at the time of estrus from the pathogenic fluid retained in the uterus. Because pregnancy diagnosis requires accuracy, as described in the section of rectal palpation, ultrasonography for pregnancy diagnosis should be performed 25 days after mating service or later.

Photographs 3-17 shows a cross section of the pregnant horn 28 days after insemination. The uterine cavity is about 2 cm in diameter and contains an embryo (E). At the time of examination, but not in the still picture, the beating of the heart can be observed on a real time basis. Improvements in diagnostic ultrasonographic techniques and equipment are expected to enable early and accurate diagnosis. However, confirming the continuance of pregnancy is necessary after early pregnancy diagnosis.

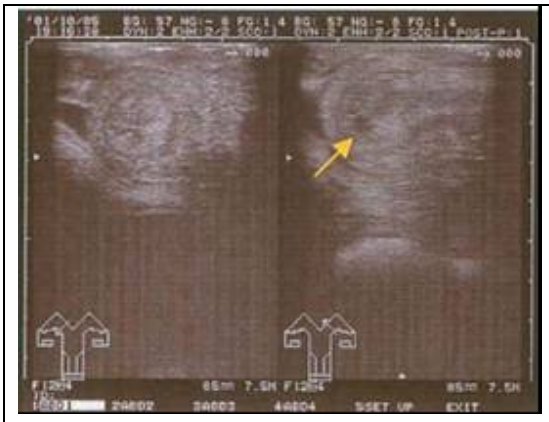	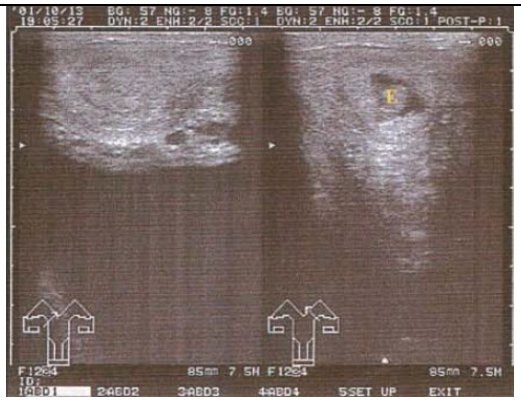
Photograph 3-16 The horn on the 20th day of pregnancy (7.5 MHz) Echo-free image 2 -3 mm in diameter are present in the lumen of the right horn that are related to the retention of fetal fluid. There are no changes in the lumen of the left horn. Diagnosing pregnancy from only these findings is difficult. The arrow indicates fetal fluid in the uterine cavity.	Photograph 3-17 The horn on the 28th day of pregnancy (7.5 MHz) The uterine cavity, which is echo-free, is dilated due to the retention of fetal fluid. An embryo (E) is present. By the stage, minute changes in the image accompanying heartbeats are confirmable during the ultrasonographic process. Thus, confirming pregnancy is possible at this stage.

Chapter 4 Guidelines for the control of reproductive disorder

As long as there is a chance of insemination, female livestock generally repeat pregnancy/ delivery according to their species-specific reproductive characteristic unless there are abnormalities in the ovarian function and accessory reproductive organs. A condition in which reproduction is temporary or persistently prevented and suspended from any cause is generically referred to as a reproductive disorder.

Cause include feeding and management factors such as the environment of cow sheds and feed used, management factors such as herd size and milking volume, personal factors of indivisual farmers such as operation ability, management ability and observation ability, obstetric factor such sterility, abortion, premature and still birth and dystocia and insemination factors such as the identification of estrous sign, management of semen and artificial insemination method. Thus causes should be identified according to individual farmer to enable them to remove or improve the cause of reproductive disorder and achieve stable breeding performance.

This chapter provides field guidelines in managing reproductive disorder of dairy cattle for farmer, inseminators and veterinarians.

4.1 Technical guidance for farmers

To maintain high lactation and continuous calving and achieve high productivity and stable management, one delivery per year should be pursued. To achieve one delivery per year, insemination must be performed at 60-90 days after calving. To that end, identifying estrous after calving is significant in stock farming and improving conception rates. As dairy cattle have been improved, there has been a dramatic improvement in milk performance. These herds do not necessarily show clear estrous signs during the period from 60-90 days after calving because this period corresponds to the lactation peak. Thus, detecting estrus is difficult. Farmers must pay the utmost attention to identify estrus at this stage since it is the basic of stock farming. The following are major points in detecting estrus.

4.1.1 Detection of estrus

Sexual behavior of female livestock in the estrus stage is known in Table 4-1. There are differences among species. Here, a detailed description of sexual behavior in cattle is presented. A cow herd continuously fed in cow sheds tends to keep standing when normal cows are lying , approach adjacent cows in an unnatural manner, come close to a person in front of them, have decreased (of increased) milk yield and have decreased appetite and considerably shorter rumination periods. The vulva is swollen and the pudendal mucosa in congested. Sticky mucus is excreted from the vulva in the proestrus stage and mucus becomes fluid as estrus advances. It is watery at the estrus peak and sperm receptively is the highest at this stage.

Table 4-1 Sexual behavior (estrous sign) in female livestock

Behavior	Cattle	Sheep	Goat	Horse
Smelling	Smelling the body and genital region of male animals.			
Urination	Frequent urination during teasing by male, pollakiuria is not an estrus sign in sheep but is characteristic of the condition accepting males in the horses.			
Crying	Normal but frequent cries			?
Exercise	Motility is generally increased. Smelling the genital region of males, females face the opposite direction to males and make a round movement			
	Mount Other female	Wag the tail. Do not mount	Mount other female	Do not mount
Posture	Stand still while males court			
	Turn the head backward and lift and bend the tail			Open and close the pudendal lips to expose the clitoris (lightening). Open the hind legs, bend the hip lift the tail
Response after mating	Bend the back and lift the tail high	None	None	None

Source Partially revised from Hafez, 1987

Estrus is a state in which a cow stands still and allows other cattle to mount it. The acts of pursuing and mounting other cattle usually last several days around estrus. Many cows in their late pregnancy period pursue and mount other estrous cows frequently. Thus, these act serve as signs for identifying estrus but are not decisive.

Table 4-2 Behavior in bovine estrous cycle

Division	Estrous cow	Non-estrous cow
Number of cows	7	7
No. of times of mounting/ hr	2-14 (9.6)	0-2 (0.4)
No. of times of being mounted/ hr	17-44 (29.6)	0-1 (0.2)
Number of steps/ hr	862-1821 (1279-4)	186-658 (313)

Source: Miyake 1996

Note: values in the parenthesis represent the means

The sexual behavior of an estrous cow is known to be more active in the morning than in the afternoon. A report shows that estrus mostly begins during the period from midnight to 6 AM and less frequently in the afternoon. The acts of standing still and allowing other cows to mount are important clues for detecting estrus when they are having exercise in the paddock or when they are raised in free stalls.

In tethered cows under drylot feeding, the presence of estrous mucus either attached to the tail or public hair or on the stall or feces in early morning often indicates. The results of a survey of the means used to detect estrus in 1,513 inseminated Holsteins in Chiba are shown in Table 4-3.

Table 4-3 Means of detecting estrus (Holsteins)

	Total	Conceived
Animal number heads	1,513	945
Total number of A.I.	4,227	1,635
Mucus	35.8%	34.5%
Vulva	21.9%	21.7%
Mounting	16.3%	17.2%
Behavior	13.9%	14.4%
Roar	9.0%	9.4%
Others	2.4%	3.1%

Source Chiba prefectural Mutual Insurance Federation of Agriculture Cooperatives (1977)

Estrus was detected by the presence of mucus in 35.8% of the cases, by swelling of the vulva in 21.9% of the cases and by mounting behavior in 16.3%.

Estrus estrous mucus in shown in photograph 4-1. A swollen vulva is shown in photograph 4-2.

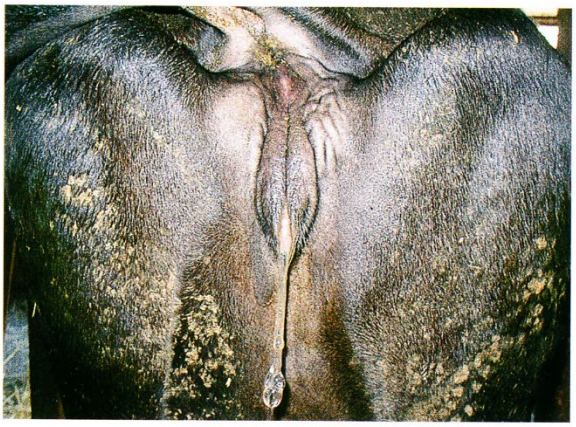

Photograph 4-1 Estrous mucus

Photograph 4-2 Swelling of the vulva

Soutce: Chiba Prefectural federation of Agricultural Aid Associations in Japan

Postpartum recovery or reproductive function takes several dozen days. The ovary immediately after calving is in a stationary state and ovarian follicles start to grow within a week. The ovaries start to accelerate their growth 10 days after calving.

The first postpartum ovulation takes place about two weeks after calving at the earliest and mostly 20 days after calving in dairy cattle undergoing normal calving. This number of days depends on age, parity, season and nutritional condition and is strongly affected by milk yield; it increases especially in high-lactating cows. However, some reports show that first ovulation occurs about 15 days after calving in high-lactating cows if they are well fed. Thus, observation of the estrus should be started as early as possible after calving (about 20 days after calving).

The condition of a cow including weak estrus and metaestrual bleeding must be observed carefully and recorded in preparation for the next estrus. As described above, failure in detecting estrus has a significant influence on dairy farming. Thus farmer should make sure to detect estrous sign, however weak estrous. Table 4-4 (p. 108) shows the rates of detecting estrus by method. There is no significant difference between twice-daily, observation at fixed time and other methods. Observation of estrus should be performed at least twice daily in the morning and evening to increase the rate of detecting

estrus and hence conception rates.

Cows should be subjected to once- to twice monthly regular reproductive examinations by a veterinarian and all cows should be examined on the 30th day after calving onwards for the presence of estrus and uterine involution to improve reproductive performance of the herd as a whole.

Table 4-4 Rate of detecting estrous in cow by different method

Methods	Presenter	Donaldson (1968)	Lauderdale (1974)	Foote (1975)	Others
3-time daily teasing		93.1%	-%	-%	-%
Mounting by other cows		81.0	-	-	-
24-hour-day monitoring		100	97-100	89	-
3-time daily, fixed-time monitoring		91	81-91	-	-
Twice daily, fixed-time monitoring		90	81-91	72	-
Observation during routine work		-	56	56	-
Chin-ball method		98	98-100	98-100	-
Heat mount detector method		-	-	-	96-98

Source Sugie, 1980

4.2 Technical guidance for veterinarians

4.2.1 Early Pregnancy diagnosis

Early identification of whether or not insemination resulted in conception helps to determine the course of action. In case of conception, for instance, preventing abortion and making calving plans. In the case of a failure, estimating the date of the next estrus and ensuring insemination. In the case of reproductive disorder, proper diagnosis and early treatment helps early recovery from these disorders.

Pregnancy diagnosis refers to a technique involving identifying the changes in the mother's body resulting from conception and the sign of pregnancy accompanying the generation of the fetus. A practical pregnancy diagnostic method must ensure early diagnosis and a rate of correct diagnosis of more than 85%. However, a rate of correct diagnosis of 100% is desirable as veterinarian are concerned. The method must also be simple, harmless to the mother and fetus and less costly.

(1) Rectal Palpation (fetal membrane slip)

This method has been widely used in the field and allows pregnancy diagnosis about 30 days after breeding onwards. However the field pregnancy diagnosis is usually made at 35-40 days after breeding. The method involves turning over the uterus, palpating the tips of the uterine horns and confirming clear fluctuation (fetal fluid) and dilation of the pregnant horn and the presence of the fetal membrane and vessels contained in the fetal membrane, as shown in figure 4-1.

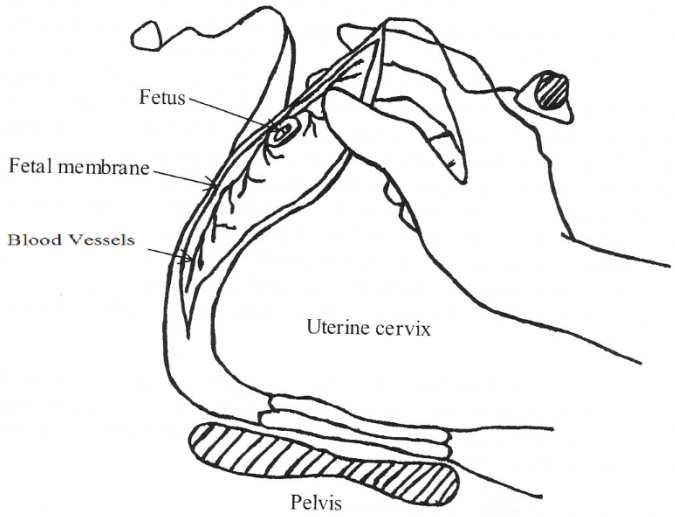

Figure 4-1 palpation region in pregnancy diagnosis

Source: Chiba Prefectural federation of Agricultural Aid Associations in Japan

Fetal membrane slipping reaction starts at the side of pregnant horn 35 days after breeding. At body of the uterus after 40 days and at both horn after 45 days, fetal membrane slipping can be diagnosed.

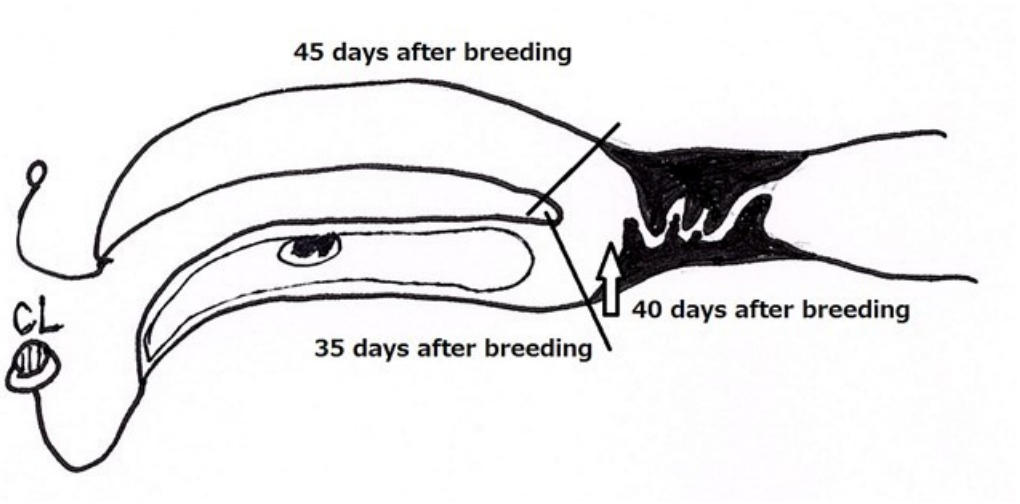

Figure 4-2 Points to be diagnosed of each days after breeding

Source: Tominaga 2018

The fetus in the fetal fluid on the 80th day of pregnancy onwards and the uterine artery and characteristic vibration in the pregnant horn on the 90th day of pregnancy onwards. However, finding of the uterine artery and vibration are not decisive indicators of pregnancy because they are occur in sterile cows with high parities. Pregnancy must be confirmed by the finding of the fetal membrane referring also to finding in the accessory reproductive organs.

Early pregnancy diagnosis allows early detection of abnormalities. It allows the detection of cows with embryonic

death and unstable pregnant condition such as the lack of development of the uterus and vessels matching the days after insemination. It allows the detection of cows that have growing ovarian follicles and contraction and thickness of the uterus so they are at risk of abortion and need treatment without hormones such as hCG.

The following summarize points to note when making pregnancy diagnosis by rectal palpation

1) Ovary

1) The number of pregnant corpus luteum, unilateral or bilateral?
2) The presence/ absence and quantity, if any, of fluid in the cavity of a pregnant corpus luteum.
3) The presence/ absence, number and size of coexistent ovarian follicles

2) Uterus

1) Whether thickening of the uterine wall is similar to that in estrus.
2) Whether contraction is similar to than in estrus.
3) Agreement between the size of the uterine horn and days of pregnancy

The size of the pregnant horn resulting from development of the fetus, fetal fluid and appendages of the fetus (based on the middle finger)

30 days of pregnancy: 2.0-2.5 finger widths
35 days of pregnancy: 2.5-3.0 finger widths
40 days of pregnancy: 3.5 finger widths

4) Confirmation of the presence or absence of expansion of the non-pregnant horn (after 35th day of pregnancy)

3) Appendage of the fetus

1) Whether it is monotocous or prolificacy. If it is prolificacy, is it bilateral of unilateral pregnancy?
2) Are the fetal fluid, fetal membrane and vessels in the fetal membrane readily palpable?
3) If the entrance of the appendages of the fetus into the non-pregnant horn confirmable (after the 35th day of pregnancy)?
4) Agreement between the vessels in the fetal membrane and days of pregnancy

30 days of pregnancy: silk thread like (size of vessels)
35 days of pregnancy: cotton thread like (size of vessels)
40 days of pregnancy: kite string like (size of vessels)

4) Others

1) The cervical canal is contracted.
2) The external pudendal lips are contracted.

The external pudendal lips of a pregnant cow Are shown in photograph 4-3

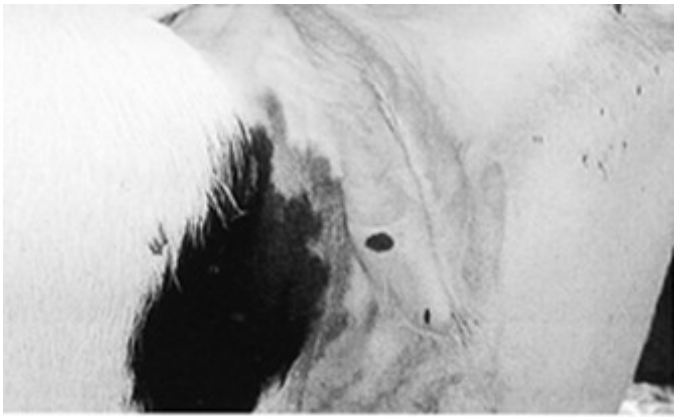

Photograph 4-3The vulva of a pregnant cow

Soutce: Chiba Prefectural federation of Agricultural Aid Associations in Japan

5) Handling of a case of pregnancy with abnormal findings

1) Treatment

If the contraction of the pregnant horn in strong, treatment with hormones such as hCG is necessary to improve luteal function and attain a stable pregnant status.

2) Reexamination

If abnormal finding are present, a reexamination is performed on the 60th to 90th day of pregnancy when implantation is completed.

Pregnancy diagnosis by rectal palpation leads to misdiagnosis in the case of pyometra and mummified fetus but differential diagnosis is not very difficult if meticulous care is taken when checking the points mentioned above. Photograph 4-4 shows pyometra.

Photograph 4-4 Pyometra

Soutce: Chiba Prefectural federation of Agricultural Aid Associations in Japan

4.2.2 An example of a comprehensive diagnosis method and treatment for the reproductive organ mainly consisting of rectal palpation

Diagnosis of ovarian function based solely on ovarian finding in rectal palpation is often inaccurate and may lead to misdiagnosis.

The possibility of misdiagnosis can be remarkably reduced by examining ovarian function through an overall analysis of finding in palpation of the uterus and cervical canal and observation of the vagina, pudendal lips and mucus as well as ovarian findings.

A comprehensive diagnosis method will be described according to table 4-5. In either case, if the first examination fails to lead to a decision, a second examination should be performed after 7-10 days.

Table 4-5 Judgement of ovarian finding from finding in the uterus, cervical canal, vagina and vulva (overall diagnosis)

		Uterine findings						Others			Judgement	Diagnosis
		Size	Shape	Contraction/elasticity	Thickness	Mucus	Cavity	Cervix	Membrane mucus	Pudendal lips		
1		2.5	Flat	-	++	+++	++++	Hard, thick, open	Plenty	Loose	? is an ovarian follicle	 Follicular cyst
2		2.0	Round	+	+	-	-	Thin	Absent	Contracted	? is the corpus luteum	 Normal
3		2.0	Oval	+	++	+	+	Slightly thick	Opaque, plenty	Slightly loose	? is an abnormal ovarian follicle	 Corpus luteum with decreased function; Abnormal ovarian follicle
4	 Ovarian findings	2.0	Round	+	+	-	-	Thin	Absent	Contracted	No effect of follicular hormones Normal luteal function	 Normal
5		2.0	Round	++	++	-	-	Open	Present	Swollen	? is the regression of corpus luteum (left) ? is an estrous follicle (right)	 Estrus

(1) Palpation of the ovary does not help determine whether there is an ovarian follicles of corpus luteum.

Is the large body in the right ovary in column 1 of table 4-5 really an ovarian follicle? The uterus is large, flat, not contracted and the uterine wall is initially thick with clear internal finding. The cervical canal is thick and its lumen is open. The vulva is significantly loose and leak a large quantity of opaque mucus. These finding are effect of E_2. Thus, the large body in the right ovary is an ovarian follicle. Because the follicle is more than 25 cm in diameter and other corpus luteum is impalpable, a diagnosis of a follicular cyst is made. A diagnosis to differentiate from the cystic corpus luteum and a luteal cyst can be made by closely examining the finding above. To treat follicular cyst, hCG and GnRH preparation are administered in most cases. Special attention must be paid to whether continued estrus is present or not.

Is the body in the right ovary in column 2 of table 4-5 an ovarian follicle or corpus luteum? The uterus is soft without intense contraction, elasticity or thickness. The cervical canal is thin, its lumen is closed and the vagina is dry. The pudendal lips are contracted. These finding are the effect of P_4. Thus, this body is the corpus luteum and judged normal because of a lack of internal feeling.

What are the bodies in the right and left ovaries in column 5 of table 4-5 Because the accessory reproductive organ show estrous findings, either one must be diagnosed as an estrous follicle. The left body with the size of an ovarian follicle lacks fluctuation by palpation and is hard so it is judged as the regressed corpus luteum.

(2) Examination luteal function and the effect of ovarian follicles

In column 3 of table 4-5, the corpus luteum and an ovarian follicle are detected in the left ovary. Are they functioning normally? The uterus is thick with internal feeling and the cervical canal is somewhat thick and open. The quantity of vaginal mucus is large for the luteal phase and the vulva is loose. These findings indicate the effect of E_2. Thus, the ovarian follicle is abnormal and the corpus luteum is not functioning normally.

For treatment, to improve luteal function and induce ovulation an luteinization of the abnormal follicle coexistent with the corpus luteum, hCG preparations and luteal hormone are administrated as required.

Finding in the accessory reproductive organs shown in column 4 of table 4-5 indicate the absence of effect of the ovarian follicle in the left ovary and normal luteal function.

Chapter 5 Application of reproductive technology by the Project in Sindh Province

5.1 The situation of Reproduction in rural area and Guidance of appropriate technology

The Project on Sustainable Livestock Development for Rural Sindh is implementing its activity in Southern parts of Sindh Province, Pakistan.

The baseline survey on small and medium scale dairy farmers conducted in the beginning of the Project revealed that majority of dairy farmers availed veterinary services only at the time of serious illness or dystocia of their animals. Dairy farmers apply traditional methods when their animals suffer from slight illness. Dairy farmers did not use services of reproductive diagnosis and treatment for reproductive disorder of their animals. Reproductive disorder is not fatal disease and does not demand emergency treatment. Dairy farmers just wait without any diagnosis and treatment of unpregnant animals until they decide to cull at some point of time. This is normal practice which has been exercised in rural Sindh. Expertise on animal reproduction in the area was underdeveloped. The Project had to start technical guidance on animal reproduction from scratch.

The situation of reproduction at Pilot Farms (Year 2014)

- Pilot Farms who keeps reproductive record …… 0 Case
- Pilot Farms who had animals receive treatment of following symptoms

	Got treatment	Yes, by Vet	Yes, by Para-Vet
An-estrus	0		
Repeat breeding	0		
Abortion	13	11	5
Retention of placenta	13	11	5
Dystocia	13	11	4

- Pilot Farms who had animals receive

Rectal palpation for pregnancy diagnosis	0 case
Rectal palpation for treatment	0 case

Figure 5-1 The situation of Reproduction at pilot farmer (year 2016)

To produce tangible results on improvement of conception rate of animals, both technical guidance to dairy farmers and to veterinary doctors are required in parallel. For dairy farmers, technical guidance on improvement of nutritious condition of animals, heat detection and reduction of stress are needed. For the veterinary doctors, training of skilled technicians who can carry out diagnosis and treatment of reproductive disorder are required. Diagnosis and treatment of reproductive disorder through rectal palpation requires profound techniques which can be developed through untiring efforts over considerable time period.

5.1.1 Reproductive situation at Pilot Farmer in rural area

The Project analyzed the data of parturition of buffalo at P/F obtained from 2014 to 2016. The month of parturition and heat were analyzed and graphed. Parturitions occur frequently in seven months, namely from May to November (See Figure 1 of line graph). Pregnancy period of buffalo is 310 days on average. Mating month is regarded as

10 months before parturition month. The month of heat, mating and conception, therefore, occurred in seven months, from July to January See Figure 5-2 bar graph). Number of buffalo came in heat in December was small, which was due to low nutrient value of roughage provided during that month. Many farmers feed their animals with wheat straw or rice straw, which are less nutrient, from the end of November to the middle of December. From the end of November to early December farmers plant legmes berseem and alfalfa, which can harvest from the middle of December to March. Berseem and alfalfa can be harvested four to five times and mixed with wheat straw or rice straw. The number of animals come in heat, therefore, increased in January.

Calving interval and first parity age of months of P/F buffalo are as follows:

- Calving interval: 19 months ± 3.2 months
  (It took over 9 months after last delivery to become conceived again)
- Age of first parity: 42.8 months ± 4.7 months

Table 5-1 Number of parturition and mating by month

	J	F	M	A	M	J	J	A	S	O	N	D
Breeding	15	9	5	5	5	7	15	16	14	16	15	9
Delivery	5	5	5	7	15	16	14	16	15	9	15	9

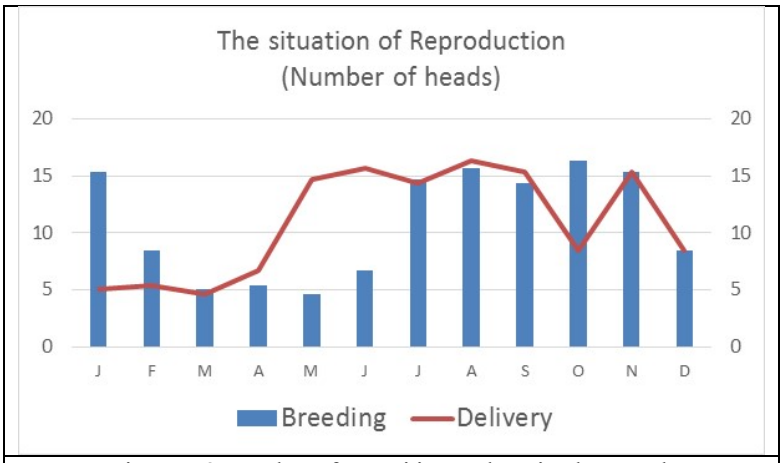

Figure 5-2 Number of parturition and mating by month

5.1.2 Improving reproduction

Reproduction can be improved in following 2 ways;

1) To achieve early age at first calving (for heifer); Improve feeding management so as to improve growth of heifers and to have first mating and conception in early age. When body weight of heifer reaches to 300kg (or 161cm heart girth), is appropriate time for mating can be taken place.
2) To achieve early conception after parturition (for parous cow); Shorten calving interval.

(1) To achieve early age at first calving (for heifer)

Cattle/buffaloes can produce milk only after she conceives and delivers a calf. Cattle in Sindh Province conceives for first time at around 2.5 to 3 years old and have first calving at the age of 3.5 to 4 years. For a heifer to get conceived in its early age, it needs to grow well and reach at early maturity. Daily weight gain of calves and heifers in rural Sindh is 0.25 kg on average, which is low and main cause of late maturity and age at first mating. . It is important to increase daily weight

gain up to 0.5kg by providing plenty of good quality hay (of those plenty of leaves) during suckling and after weaning up to 8 months of age, followed by provision of plenty of good quality of roughage (of those plenty of leaves) after 8 months of age. The heifer, can reach to optimum body weight 279 kg at the age of 1 and half years. This is appropriate body weight for first mating.

[Example of buffalo]

- The present buffalo growth in rural Sindh: 1064 days (about 3 years old) are needed to reach appropriate body weight for first mating

  Birth weight of 34kg + (1064 days x 0.25 kg) = 300kg
- In case of improved growth rate (0.5Kg/day) : The heifer at the age of 532 days (about 1.5 years old) shall reach appropriate body weight for first mating.

  Birth weight of 34 kg + (532 days x 0.5kg) = 300kg

Table 5-2 Quick chart for body weight and heart girth

Heart Girth	Estimated weight	Heart Girth	Estimated weight	Heart Girth	Estimated weight	Heart Girth	Estimated weight	Heart Girth	Estimated weight	Heart Girth	Estimated weight	Heart Girth	Estimated weight	Heart Girth	Estimated weight
65	40	91	62	117	120	143	214	169	344	195	510	221	712	247	950
66	40	92	63	118	123	144	218	170	350	196	517	222	720	248	960
67	40	93	65	119	126	145	223	171	355	197	524	223	729	249	969
68	40	94	67	120	129	146	227	172	361	198	531	224	737	**250**	979
69	41	95	68	121	132	147	232	173	367	199	539	225	746	251	989
70	41	96	70	122	135	148	236	174	373	**200**	546	226	755	252	1000
71	42	97	72	123	138	149	241	175	379	201	553	227	763	253	1010
72	42	98	74	124	142	**150**	245	176	385	202	561	228	772	254	1020
73	43	99	76	125	145	151	250	177	391	203	568	229	781	255	1030
74	43	**100**	78	126	148	152	255	178	397	204	576	230	790		
75	44	101	80	127	152	153	260	179	403	205	583	231	799		
76	45	102	82	128	155	154	264	180	410	206	591	232	808		
77	45	103	84	129	159	155	269	181	416	207	599	233	817		
78	46	104	86	130	162	156	274	182	422	208	606	234	826		
79	47	105	89	131	166	157	279	183	429	209	614	235	835		
80	48	106	91	132	170	158	284	184	435	210	622	236	845		
81	49	107	93	133	173	159	290	185	442	211	630	237	854		
82	50	108	96	134	177	160	295	186	448	212	638	238	863		
83	51	109	98	135	181	161	300	187	455	213	646	239	873		
84	52	110	101	136	185	162	305	188	462	214	654	240	882		
85	53	111	103	137	189	163	311	189	468	215	662	241	892		
86	55	112	106	138	193	164	316	190	475	216	670	242	901		
87	56	113	109	139	197	165	322	191	482	217	678	243	911		
88	57	114	111	140	201	166	327	192	489	218	687	244	920		
89	59	115	114	141	205	167	333	193	496	219	695	245	930		
90	60	116	117	142	210	168	338	194	503	220	703	246	940		

(2) To achieve early conception after parturition (for parous cattle/buffalo)

(Early reproductive diagnosis after parturition)

Cattle requires 30 to 45 days to recover their uterus after parturition. To mate your cattle earlier after parturition to get it conceived again, your proactive action will be needed. Call a veterinary doctor to have early reproductive diagnosis of cattle at 30 days after its parturition. Necessary treatment of problem cows by a veterinarian doctor at that point of time will

allow cattle to come in heat and get conceived again in early stage. Short delivery interval means more number of parturition in their life time. It also means that cow produce more milk in her life time and income of the farmer increased. .

(Shortening calving interval)

a. Cattle

It might be a little bit difficult target to get one calving per year. Earlier a cow get conceived, shorten the calving interval. As a result, total milk production of a cow in her lifetime will increase.

One year is comprised of 365 days. Pregnancy period of a cow is 285 days on average. Deducting 285 days from a year equals to 80 days. Supposing recovering period of uterus as 30 days on average, 50 days (80 days minus 30 days) will be left for next conception. If a cow comes in heat again during these 50 days of period and get conceived, 'one delivery per year' can be achieved. Heat cycle of a cow is 21 days on average. You will have 2 chances of your cow becomes in heat and get conceived during this period.

Example: Parturition interval : Case of Cattle

1 year (365 days)	
Pregnancy period 285days ±10 days	**80 days**

Figure 5-3 Pregnancy period of a cow

b. Buffalo

Pregnancy period of buffalo is longer than cattle, which make it more difficult to get one calving per year as compared with cattle. Earlier a buffalo get conceived, shorter calving interval becomes. As a result, total milk production of a buffalo in her lifetime will increase.

One year is comprised of 365 days. Pregnancy period of a buffalo is 310 days on average, which is 25 days longer than cattle. Deducting 310 days from a year equals to 55 days. Supposing recovering period of uterus as 30 days, 25 days (55 days minus 30 days) will be left for next conception. If a buffalo comes in heat again during this 25 days of period and get conceived, 'one delivery per year' can be achieved, which seems difficult for a case of buffalo. Heat cycle of a buffalo is 21 days on average. If mother buffalo comes in heat and get conceived during this period, you can achieve the target. It is, however, difficult for a case of buffalo so the ideal calving interval would be a little bit longer than those of a cow.

Example: Parturition interval : Case of Buffalo

1 year (365 days)	
Pregnancy period 310days ±10 days	**55 days**

Figure 5-4 Pregnancy period of a buffalo

5.2 Detecting heat and reproductive record of Kundhi buffalo

5.2.1. Detecting heat of Kundhi buffalo

Currently there is no detailed data of heat phenomenon of Kundhi buffalo available. Data of Nili Ravi buffalo breed, therefore, is used for explanation below. Comparing with cattle, it seems quite difficult to detect heat sign of buffalo.

Buffalo comes in heat mostly in the night, i.e. 85% heat is appeared in the night time. It is, therefore, difficult for farmers to detect their heat sign.

Table 5-3 Heat sign of Nili Ravi buffalo breed detected by time

	Time	%	
The night	18:00 - 22:00	19	85
	22:00 - 02:00	40	
	02:00 - 06:00	26	
The day	06:00 - 12:00	4	15
	12:00 - 18:00	11	

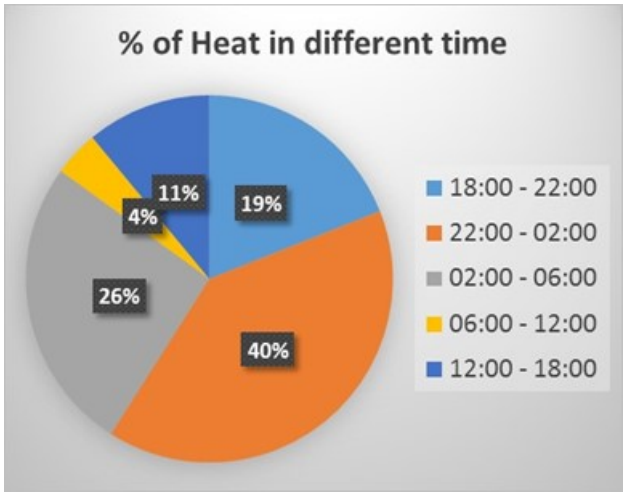

Figure 5-5 Heat sign of Nili Ravi buffalo breed detected by time

Source: National Agricultural Research Center

Besides, characteristics of buffaloes' heat sign are different from cattle, which are explained below;

1) Mounting with both female animal, i.e. courtship display, are rarely seen. (buffalo mounted by fellow buffalo is in heat).
2) Mucus from external genitalia is not strongly correlated with heat sign.
3) Only around 30% of buffalo bellowing at the time of heat.
4) Heat period is short.
5) Silent heat (heat without apparent sign) frequently occurs.

Heat can also be detected from phenomenon such as decrease of milk production, becoming fidget, buffalo does not care even their hind legs are touched.

	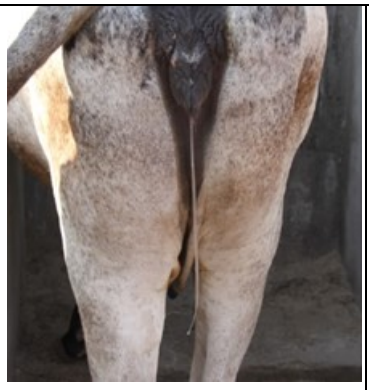	
Photograph 5-1 Swelling of external genitalia	Photograph 5-2 Mucus from external genitalia	Photograph 5-3 Natural mating

5.2.2 Frequency of heat detection observation for buffalo

Normally frequency of observation for heat detection can be set as 3 times in a day, namely, morning, midday and evening. At least 10 minutes per time observation are recommended. Observation of your herd in the paddock or grazing field allows to check mounting behavior of buffalo so that detection rates can be increased. As mentioned above, for the case of buffaloes, their heat occurs mostly in the night, i.e. 19% during 18:00 to 22:00 and 40% during 22:00 to 2:00. It is, therefore, recommended to observe one more time before you go to sleep in the night.

5.2.3 Reproductive record

Let's improve reproduction of your cattle together with veterinary doctors.
To improve reproduction of your cattle, record on reproductive activities of your cattle is essential step.
Let's look at the calendar below, learn how to record and do it!

Currently farmers in Sindh province do not take any measures against their cattle which have been non pregnant for a long time. Proper reproductive diagnosis and treatment is almost non-existent in rural areas. There are few numbers of skilled veterinary doctors specialized in reproductive health as well.

To improve reproduction of your cattle, records of reproductive activities of your cattle is necessary. This record will help for proper diagnosis and treatment by veterinary doctors. Let's start recording.

As a first step, you enter the name of female cattle/buffalo. Any calendar is used for recording. Following information should be noted down on day each activity is taken place.

1) Record of Parturition: Name of mother
2) Record of Heat: Name of female cattle/buffalo comes in heat
3) Record of Mating: Name of female cattle/buffalo mating, type of mating, i.e. either natural mating (NM) or artificial insemination (AI), Name of bull
4) Other information: Abortion, Sold out, Dead and so on.

Sun.	Mon.	Tue.	Wed.	Thu.	Fri.	Sat.
Note: NM: Natural mating A I : Artificial Insemination				1	2	3
4	5 Basir, Heat	6 Basir, NM	7	8	9	10 No.211, Died
11	12	13	14	15 Badin, Heat	16	17
18	19 Tand, Abortion	20	21	22 Memon, Delivery	23	24
25	26 Hyde, AI	27	28	29 Tand, Sold	30	31

Figure 5-6 The calendar of reproductive record

5.3 Basic treatment technics taught in Sindh province by the Project

5.3.1 Hormone injection

Hormone injection should be given as per necessity and limited as little as possible. Hormone can cause accident if it is leaked and adhered to fingers. PGF_{2a} adhered to fingers of pregnant women may cause abortion.

Disinfection of body area for hormone injection should be encouraged. PGF_{2a} multiplies bacteria. Hormone injection on unhygienic body area might cause gangrene of that area.

5.3.2 How to inject medicine into uterus through cervical canal by recto-vaginal method

To inject medicine into uterus for treatment and cleansing, a tube needs to be inserted into uterus via cervical canal. Use of metal tube made for this purpose is preferable. In case metal tubes are not available, insemination gun or plastic tube can be used. Tubes are used along with 50 mL capacity disposable syringe. Set a syringe into a tube.

(1) Types of tubes for injection

1) Japanese made metal tube

Syringe with thick inlet is used for Japanese metal tube.

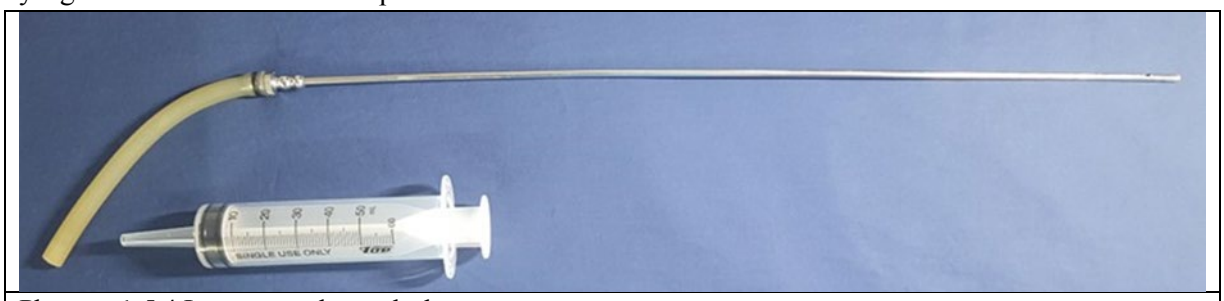

Photograph 5-4 Japanese made metal tube

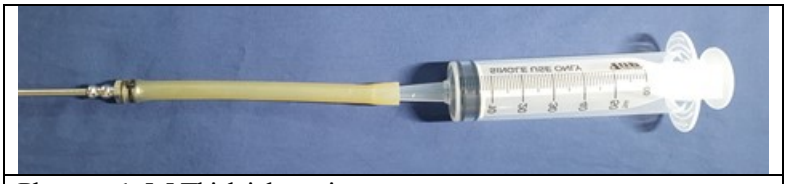

Photograph 5-5 Thick inlet syringe

2) Plastic tube

Plastic tube is available in local markets in Pakistan. Plastic is soft and easy to bend. Handling of tubes for injection is, therefore, a bit difficult. Use thin inlet no. 21G x 1 1/2.



Photograph 5-6 Plastic tube for injecting medicine

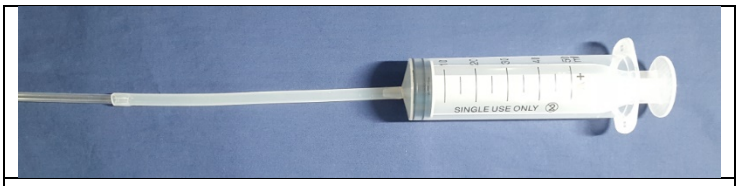

Photograph 5-7 Thin inlet syringe

3) Insemination gun

Cut a sheath pipe at a stopper point. Attach syringe with insemination gun.

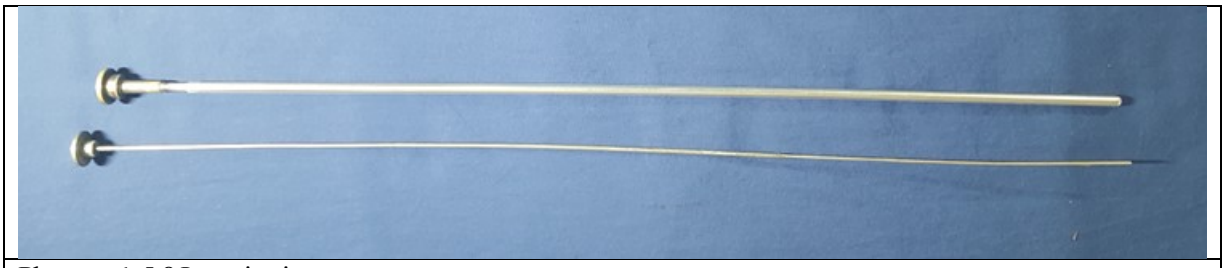

Photograph 5-8 Insemination gun

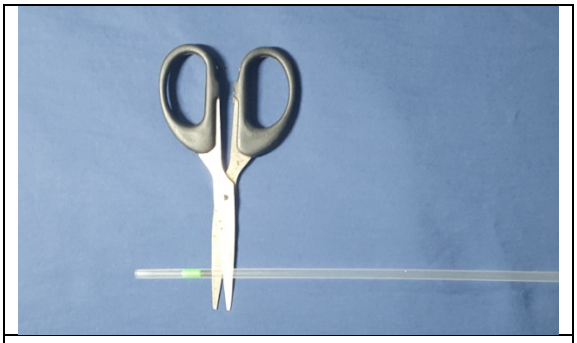

Photograph 5-9 Point to be cut before attaching syringe

When sheath pipe for AI is used for irrigation uterus, some inventive measures are required such as making a hole at a side of a pipe,

(2) Preparation

Insert a hand into rectum as per procedure of inserting insemination gun for AI. Cut nails of a hand short and smoothen surface of cut end of nail into with nail file beforehand not to damage rectal mucous membrane. Disinfect tubes with alcohol cotton to keep tubes hygienic.

(3) Inserting a tube

Put a glove for rectal palpation on one hand to be inserted into rectum. It is preferable to insert non-dominant hand since dominant hand can be free for recording and other activities. Wet surface of a glove with soapy water. Wash bovine vulva with antiseptic solution water and disinfect it with alcohol cotton. Wipe vulva with alcohol cotton from center to outer side until vulva become clean. When alcohol cotton get dirty, replace it with new one. Keep wipe it until no stain on surface of alcohol cotton is found. Open bovine vulva with a thumb and a forefinger of the hand without a glove and insert a tube into vagina.

When a tube is came off for any reasons, repeat same procedure as mentioned above.

Insert a tube gradually for about 10 cm with slightly upward slope. Once a tip of a tube pass through a vestibule of vagina, level a tube and insert it further deep. Hold a tube while pushing it slightly when a tip of a tube reaches near external os.

Insert a hand wearing a glove gradually into rectum. Do not insert a hand forcibly when rectal contraction motion of a cattle or a buffalo is strong. Adjust force with strength of rectal contraction motion and insert a hand gradually. Discharge air in rectum if any before handling a tube. Air in rectum expands rectum, which make handling a tube difficult.

Insert a hand further deep. Grasp and hold cervical canal from rectal wall. Hold external opening of cervical canal of the side of a hand gently as wrapped it with a palm. Place a little e finger and a third finger side and bottom of cervical canal. Bring a tip of a tube near external opening of uterus into external opening of cervical canal. Drawing below shows good example and wrong example of holding cervical canal

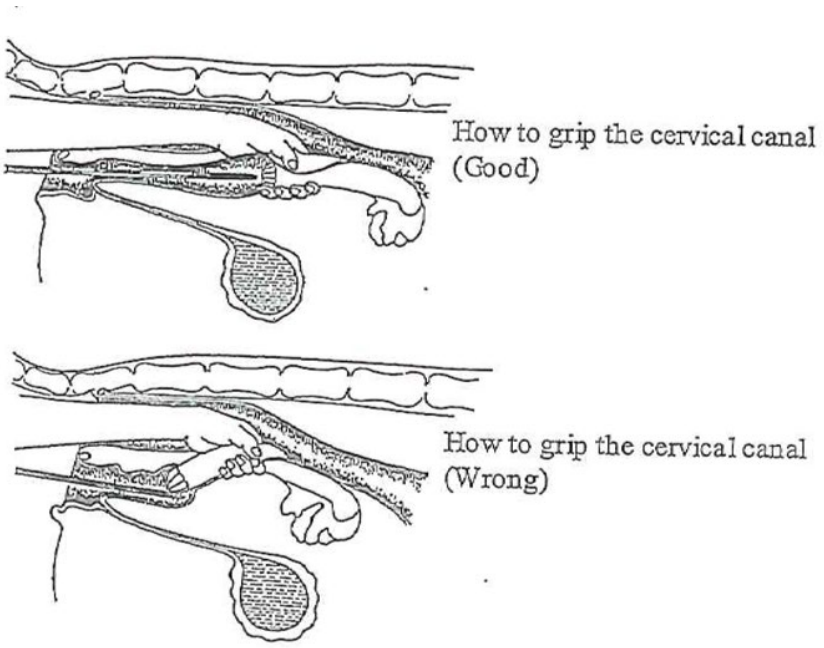

Figure 5-7 Good and wrong method for cervical canal grip

Once a tube is inserted into cervical canal, place a hand further forward along with a tip of a tube and insert a tube deep further. There are irregular spiral fimbria and stricture inside cervical canal, which make inserting a tube difficult.

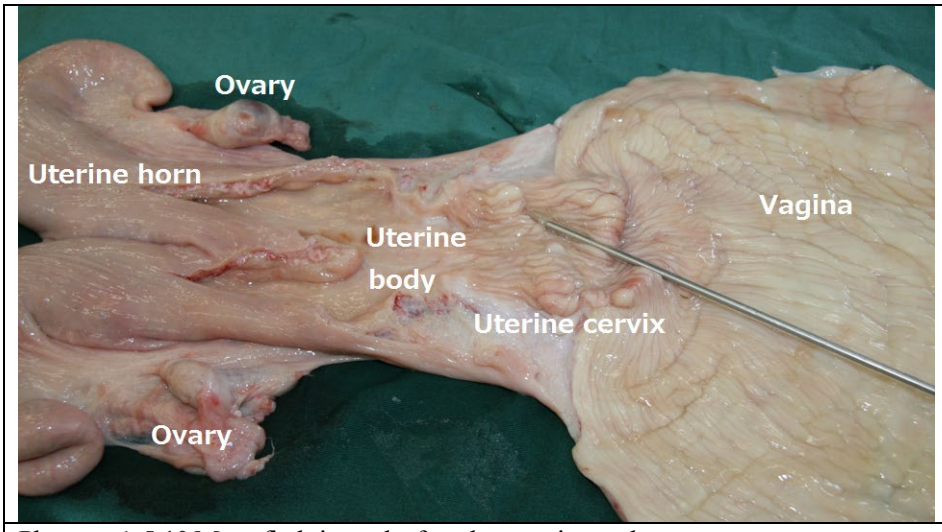

Photograph 5-10 Many fimbria can be found on cervix canal

Soutce: Chiba Prefectural federation of Agricultural Aid Associations in Japan

Never insert and push a tube by force, otherwise it injures mucous membrane and cause bleeding. If a tip of a tube is stuck, pull a tube back to the side of a hand and move a tip in another direction, then push it forward again. It is easier to handle a tube by moving cervical canal with a hand holding cervical canal than moving a tube in such a case.

Photograph 5-11 Correct way of holding a cervix

Photograph 5-12 Holding a tube lightly



Photograph 5-13 Don't push a tube strongly

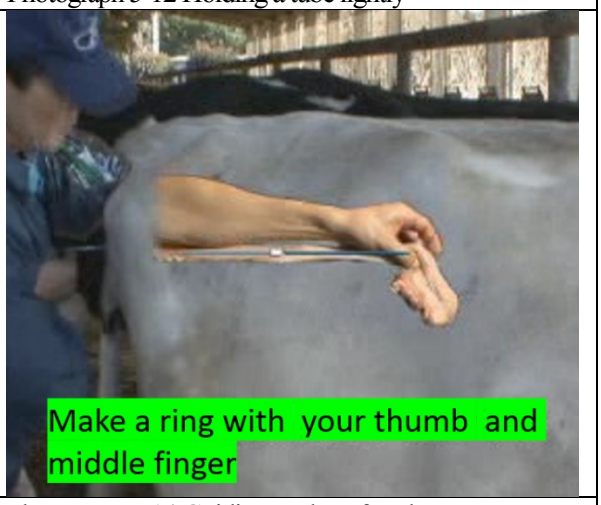

Photograph 5-14 Guiding a edge of a tube

5.3.3 Injection of medicine and cleansing uterus

Injection of medicine and cleansing uterus is comparatively easy during estrus since cervical canal is open. However, in general, treatment is performed during luteal when cervical canal is closed. The injection and cleansing is, therefore, difficult to perform. In such a difficult case, inject estrogen 3 days before treatment. With effect of estrogen, cervical canal is open, which makes injection and cleansing easy.

5.3.4 Medicine for uterus injection

(1) Isodine solution for animals (Popidone iodine)

For Uterine injection and external injury This is the solution of povidone iodine (PVP-I), it is mixed polyvinyl pyrrolidone and iodine. This drug has a strong bactericidal power of iodine. Moreover, it reduces irritancy of iodine.

[Ingredients and quantity]

It contains 20 mg popidone iodine (effective iodine 2 mg) in 1 mL solution. It stimulates uterus and renew endometrium.

Perform reproductive diagnosis 30 to 40 days after parturition. Inject iodine solution to those cattle and buffaloes whose uterus are delay in recovery and ovary is inactive. Iodine solution is effective for multiparous cattle and buffaloes

with normal uterus and inactive ovary a few months after parturition as well. Iodine solution inject does not affect quality of milk. Farmers, therefore, do not need to stop milk supply to markets like anti-biotic injection.

In the case of application of iodine solution to buffalo in Sindh, iodine solution caused irritation and sorrow. 50% diluted iodine solution with disinfected physiological saline solution, therefore, is applied to buffalo in Sindh. 50mL iodine solution is used for Holstein cattle whose uterus is big whereas 30mL iodine solution is enough for Pakistani buffalo whose uterus is small.

(2) Anti-biotics

Inject anti-biotics when bacteria cause inflammation of uterus. There are various kinds of anti-biotics but apply penicillin first.

5.3.5 Improvement of conception ratio

Detection of estrus is getting more and more difficult according to the extension of the numbers of cows reared, the improvement of milking cows with a high milk production and the changes of the circumstances of feeding and management of cow. Thus the dependence on the techniques for estrus and ovulation synchronization in the reproductive management is very high. To reply this requirement the techniques for estrus and ovulation synchronization have been vigorously developed and widely applied especially in USA and Europe. The advantage of this technology is that it can succeed in conception to some extent without rectal palpation skills but with use of hormone injection or CIDR. The disadvantage is that technicians have to visit farms several times and high cost of hormone.

Japanese technique for reproductive disorder treatment apply diagnosis of external examination and rectal palpation of individual animal and treatment on the basis of diagnosis result. Only skillful technicians can perform diagnosis, which can be disadvantage, but this method can save costs of hormone. Japanese method is much fit for the situation in Pakistan.

5.3.6 Case study of reproductive treatment in the Project

Ovsynch and CIDR are the reproductive techniques easily applied by technicians who cannot perform rectal palpation. The Project treated 10 heads of buffalo with Ovsynch. Eight among 10 heads (80%) showed estrus sign. Five out of 10 heads conceived, which was 50% of Ovsynch treated buffaloes and 62.5% of buffaloes that showed estrus sign. The Project treated 11 heads of buffaloes with CIDR. Seven among 11 heads showed estrus sign. Five out of 11 heads conceived, which was 45.5% of CIDR treated buffaloes and 71.4% of buffaloes that showed estrus sign. The both estrus and conception rate were comparatively high in both Ovsynch and CIDR methods.

HCG and Estrogen hormone treatment are performed based on results of reproductive diagnosis through rectal palpation. The conception depends on accuracy of diagnosis and rely on skills of technicians. The conception rate, therefore, was lower than Ovsynch and CIDR methods as expected. With HCG treatment, conception rate was 44.4% and 37.5% with Estrogen hormone treatment.

Four among 11 buffaloes treated with CIDR were heifers. All 4 heads (100%) showed estrus sign. According to literatures, heifers tend to show higher response against CIDR treatment than parous buffaloes. Same tendency was confirmed in the Project data. In case of Murrah buffalo in Italy, CIDR treatment achieved high conception rates. The cost of CIDR is however, as high as Rs. 2,300, which might not be easy to apply by economically disadvantaged small scale farmers.

Table 5-4 Results of reproductive treatment by the Project

Treatment		Animal Shows Heat Signs		Pregnancy		
Name	Heads	Yes	%	Heads	% of Treat.	% of Heat
Ovsynch	10	8	80	5	50.0	62.5
HCG	13	9	69	4	30.8	44.4
CIDR	11	7	67	5	45.5	71.4
Estrogen	12	8	67	3	25.0	37.5

a) Ovsynch method

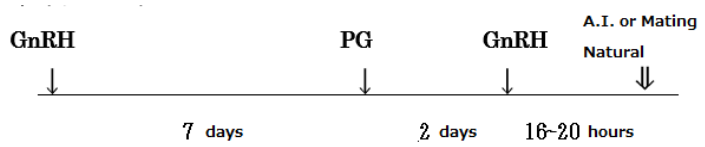

Method of applying regular insemination regardless of estrus sign

This method does not need accurate reproductive diagnosis and often applied in large scale farms in North and South America. It may cause deterioration of ability of reproductive diagnosis and treatment of veterinary doctors and overuse of medicines. In some regions of Japan, this phenomenon have been happening.

a) CIDR method (Ovsynch with combination use of P_4D)

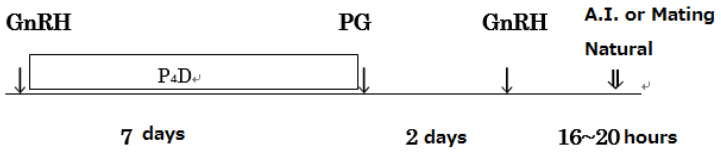

Ovsynch with combined use of progesterone device placed in the vagina

When ovsynch is used regardless of estrus cycle, timing of estrus become varied in each animal. Some animals ovulate without any estrus sign. Placing progesterone device (P_4D) easy breed in the vagina before treatment for 7 days allow delay estrus and ovulation leading in less variation of estrus sign among herd.

c) Cattle and buffaloes to be treated by Ovsynch and CIDR methods

Chiba prefecture cooperative in Japan apply Ovcynch and CIDR for the following cases;

a. Not showing estrus sign for unknown reason more than 5 months after parturition
b. Not conceiving for a long period though animal shows estrus sign
c. In summer when estrus sign is weak
d. Cow with follicular cyst

In all above cases, treatment is performed when uterus of animals is normal condition. In any case, good results of treatment depend on correct diagnosis prior to treatment. In the Project area, there are few cases of abnormal uterus conditions. Treatment by Ovsynch and CIDR, therefore, is expected to achieve good results.

5.3.7 Other advice on treatment

(1) Treatment of insistent cyst

Inject liver tonic every other day for 5 times.

(2) Luteinization failure

Inject thyradin (thyroid hormone) 10cc ampoule every other day for 3 times.

(3) When endometritis is suspected after AI

Inject penicillin 30 minutes after AI.

5.4 Training on reproductive disorder by the Project

Training on reproductive disorder is comprised of 10 days basic training and 5 days refresher training. In a basic training, basic diagnosis of reproductive disorder through external examination, vaginal examination and rectal palpation is taught to trainees. Trainees are expected to understand basis of proper diagnosis and proper recording on a record sheet for rectal palpation thoroughly. The Project award a certificate of training to those trainees who achieve remarkable results during a training.

After a training, trainees are expected to practice diagnosis and record a result of diagnosis onto a record sheet continuously in their localities to accumulate their practical experiences. The Project assesses understanding and gained techniques of each trainee 4 to 6 months after 10 days basic training.

The Project selects trainees who make remarkable progress of gaining technique for 5 days refresher training. Early pregnancy diagnosis and treatment of reproductive orders are taught in 5 days refresher training.

A few months after a refresher training, the Project visits fields where trainees of 5 days refresher training are practicing diagnosis and treatment to evaluate their performance. Those who pass the Project's evaluation criteria will get permission for performing treatment from that time on.

5.4.1. Ten days basic training

(1) Selection of trainees

The Project requests Deputy Directors of District Livestock Office to nominate candidate for 10 days beginners training. Upon receipt of name of nominees, in charge of the Project prepares list of candidate for selection. Trainees are selected based on the criteria below:

1) S/he is a veterinary doctor.
2) S/he has willingness to perform rectal palpation, though never perform before.
3) S/he is engaged with field activities in more than 60% of her/his working hours. (Her/his office work should be less than 40% of her/his working hours.)
4) His/her condition allows him/her to practice rectal palpation continuously after trainings.
5) S/he is 35 years old or below. (Special provision of exemption of age limit can be given according to situations)
6) S/he can attend all 10 days training.

NB: 3 days' delay for attending training is counted as 1 day absence. Anyone who is absent for 3 days or more during 10 days training is not entitled to receive completion certification of a training.

(2) Agreed terms to be shared with trainees on last day of 10 days basic training

1) Accumulation of practical experience after a training

Trainees learn basic knowledge of proper reproductive disorder diagnosis in short period. Trainees, therefore, need to accumulate practical experience by themselves after training.

2) Selecting farm for practice

Generally speaking, a farmer does not like a beginner technician to diagnose his/her animals. Trainees have to find a farmer who can trust them to diagnose his/her animals. It is ideal if trainees can find a farmer of his/her relatives, friends, acquaintances. It is better to select a farmer rearing more heads of animals. Trainees should not start practicing diagnosis at a small scale farm. In case trainees practice diagnosis in pilot farms and pilot villages of the Project, s/he has to be accompanied by experienced technicians and practice under guidance of them.

3) Ideal initial practice by trainees by themselves

Once a farm for practice is found and a farmer is agreed, a trainee select a few female buffalo to be diagnosed on a regular basis. A trainee diagnoses animals on a day of heat (0 day), a next day of heat, i.e. ovulation day (1st day), 7th day, 14th day and before next heat, respectively and make record on a record sheet for rectal palpation properly. This exercise is very effective for beginner technicians.

4) Recording on record sheet for rectal palpation

Proper recording is important. Trainees must not write unclear or unsure things. If trainees pretend to understand and write unclear or unsure things, s/he never improve his/her skills. It is often found a case which is difficult to diagnose even by 5 to 10 years experienced technicians. For that difficult cases, technicians revisit a farm for diagnosis a few days later.

5) Utilizing textbook

The Project distributes 'text for diagnosis and treatment of reproductive disorder in dairy cattle and buffalo' to trainees. Trainees should visit a farm along with this text book and fully utilize it. Trainees are advised to read 'Introduction' of the textbook first. Background of developing the textbook and how to use it are explained in the 'Introduction' The textbook is a guideline for trainees to improve their skills.

5.4.2 Five days refresher training

(1) Selection of trainees

The Project visits a farm where trainees practice diagnosis and evaluates skills of trainees of 10 days basic training. Selection criteria for 5 days refresher training is as follows;

1) S/he continues practicing diagnosis after 10 days basic training and can perform proper diagnosis.
2) S/he does not participate in 10 days basic training but can perform proper diagnosis through rectal palpation.

3) S/he is engaged with field activities in more than 60% of her/his working hours. (Her/his office work should be less than 40% of her/his working hours.)

4) His/her condition allows him/her to continue diagnosis of reproductive disorder and treatment after trainings.

5) S/he is 38 years old or below. (Special provision of exemption of age limit can be given according to situations)

6) S/he can attend all 5 days training.

NB: 3 days' delay for attending training is counted as 1 day absence. Anyone who is absent for 2 days or more during 5 days training is not entitled to receive completion certification of training.

(2) Agreed terms to be shared with trainees on last day of 5 days refresher training

Importance of record of rectal palpation

Proper record of diagnosis through external examination, vaginal examination and rectal palpation is important. Normally a technician visit a farm biweekly for diagnosis. Result of each diagnosis is recorded. Biweekly diagnosis and recording should be continued even after an animal become pregnant. This diagnosis prevents an animal from abortion due to abnormal CL or small CL. Even an animal abort, immediate treatment can be performed. Regular diagnosis can be exempted after 5 months of pregnancy. Ovarian cyst can be inherited from mother to calves. In case mother has ovarian cyst and she gives birth to a female calf, there is high possibility for a female calf inherit ovarian cyst. Such a calf is better to be eliminated. Record of diagnosis is useful for judging the case.

Reference

Japan International Cooperation Agency (January 2016), Project Progress Report (Second Year) of the Project on Sustainable Livestock Development for Rural Sindh "PSLD", Tokyo, JICA, pp 51

Japan International Cooperation Agency (February 2017), Chapter 3 Output 1 in *Project Progress Report (Third Year) of the Project on Sustainable Livestock Development for Rural Sindh "PSLD"*, Tokyo, JICA, pp 38-43

Japan International Cooperation Agency (February 2018), Chapter 3 in P*roject Progress Report (Forth Year) of the Project on Sustainable Livestock Development for Rural Sindh "PSLD"*, Tokyo, JICA, pp 39-45

Japan Livestock Technology Association (March 2004), Artificial Insemination Manual for Cattle, Tokyo, Japan Livestock Technology Association

Japan Livestock Technology Association (March 2002), Manual for Diagnosis and Treatment of Reproductive Disorder in Dairy Cattle, Tokyo, Japan Livestock Technology Association